



Surgical Planning Laboratory
Brigham and Women's Hospital
Boston, Massachusetts USA

a teaching affiliate of
Harvard Medical School

3D VISUALIZATION OF DICOM IMAGES FOR RADIOLOGICAL APPLICATIONS

Sonia Pujol, Ph.D., Harvard Medical School

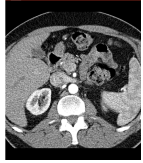Director of Training, National Alliance for Medical Image Computing

Kitt Shaffer, M.D., Boston University

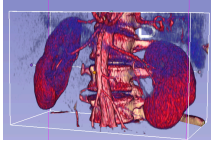
Vice-Chairman for Education, Boston University School of Medicine



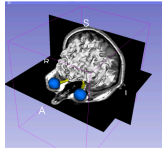
Overview



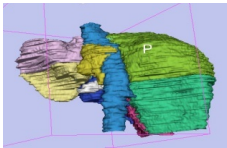
Part 1: DICOM data loading in 3DSlicer



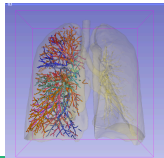
Part 2: 3D Interactive exploration of thoraco-abdominal CT data using Volume Rendering



Part 3: 3D Interactive exploration of MR head data using Surface Rendering



Part 4: 3D interactive exploration of the segments of the liver using Surface Rendering

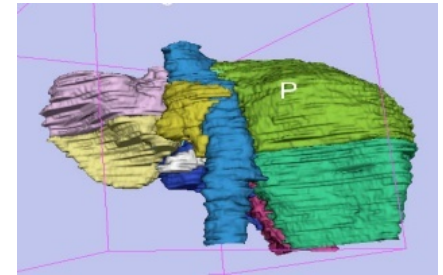
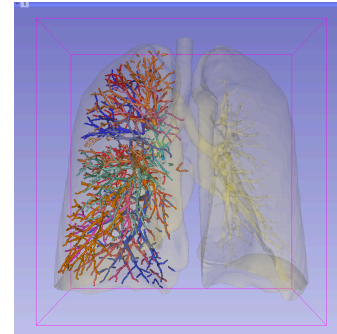
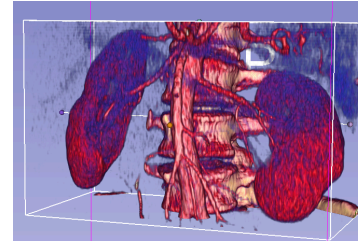


Part 5: 3D interactive exploration of the segments of the lung



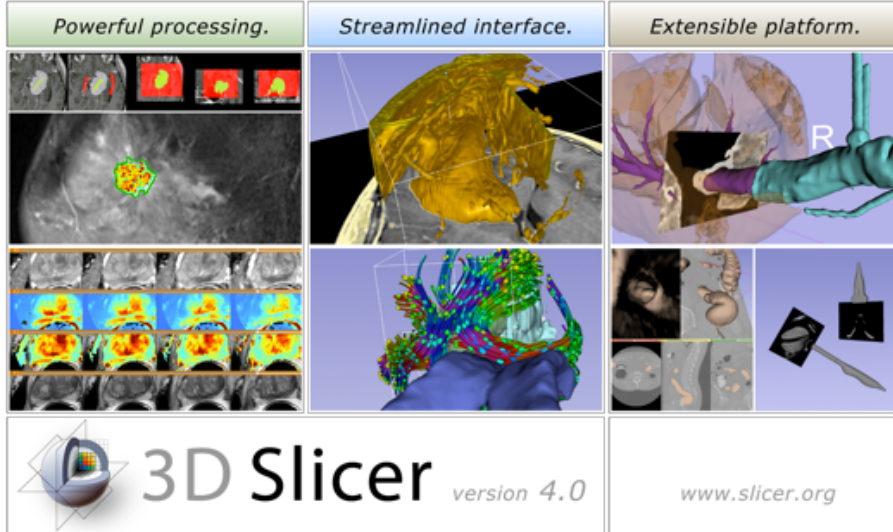
3D Visualization of the Anatomy

Following this tutorial, you will be able to **load and visualize volumes** within Slicer4.2, and to **interact in 3D** with structural images and models of the anatomy.





3DSlicer



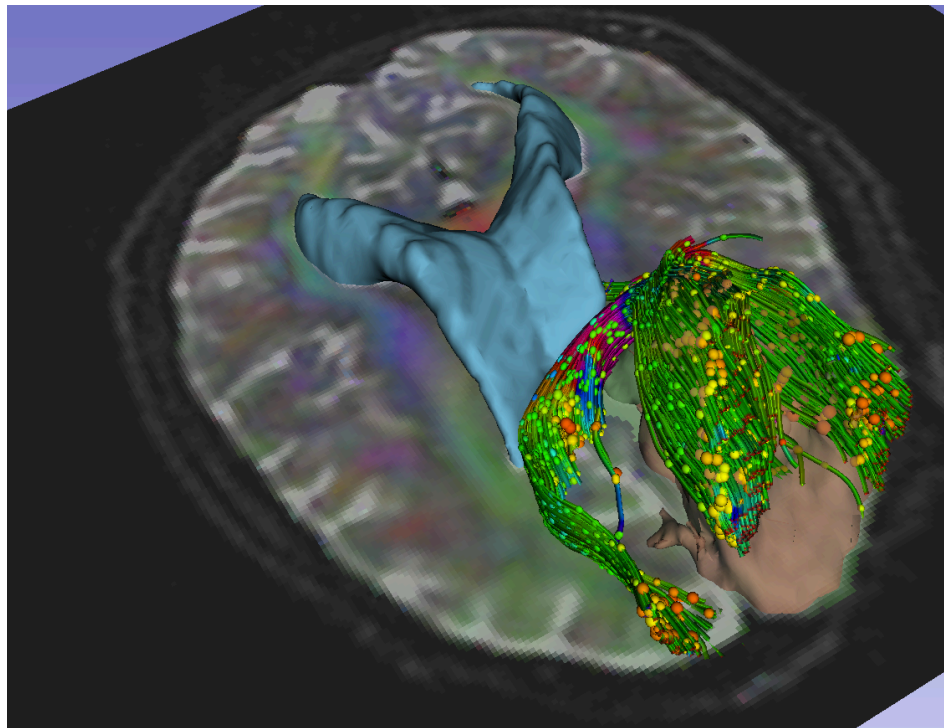
Slicer is a freely available **open-source** platform for segmentation, registration and 3D visualization of medical imaging data.

3DSlicer is a **multi-institutional effort** supported by the **National Institute of Health**.



3DSlicer

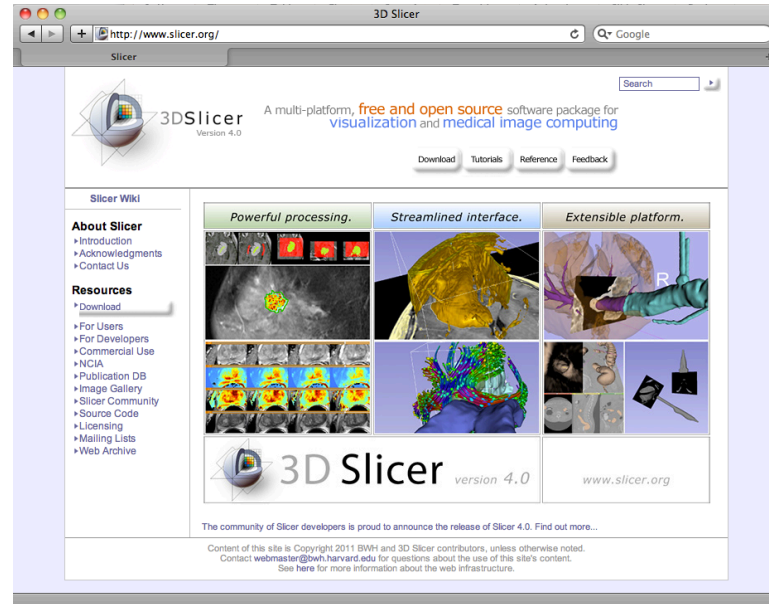- An **end-user application** for image analysis
- An **open-source environment** for software development
- A software platform that is both **easy to use** for clinical researchers and **easy to extend** for programmers





www.slicer.org

3DSlicer version 4.2
is a multi-platform
software running on
**Windows, Linux,
and Mac OSX.**



Disclaimer

It is the responsibility of the user of 3DSlicer to comply with both the terms of the license and with the applicable laws, regulations and rules. **Slicer is a tool for research, and is not FDA approved.**



3DSlicer History

- 1997: Slicer started as a research project between the Surgical Planning Lab (Harvard) and the CSAIL (MIT)

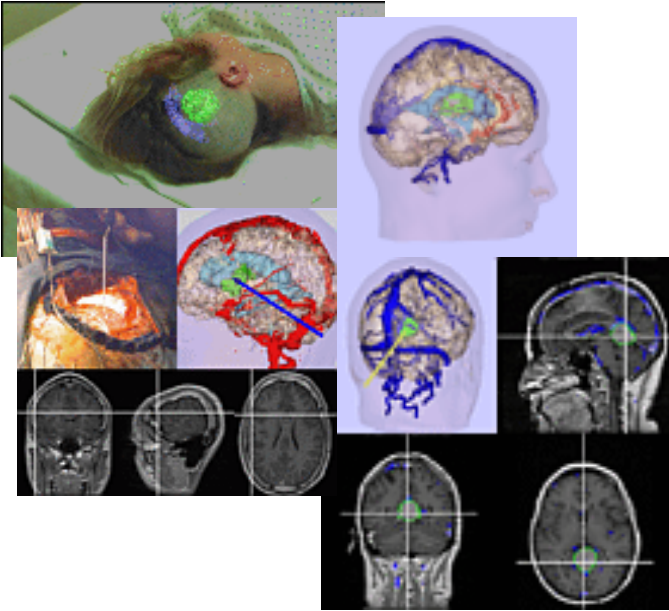
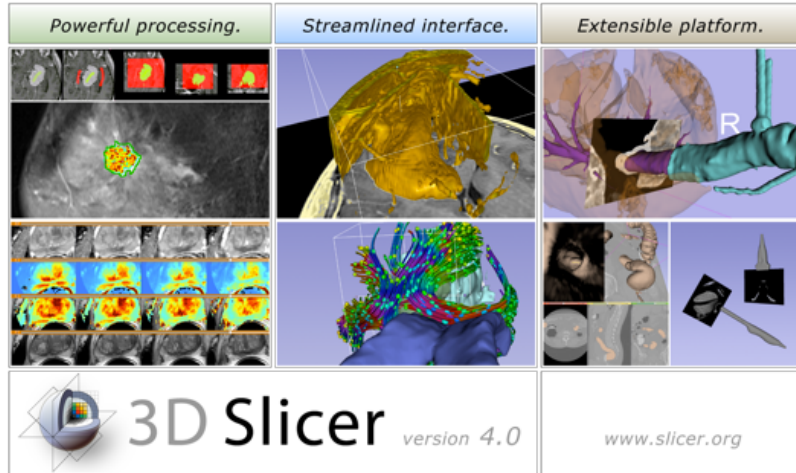


Image Courtesy of the CSAIL, MIT



3DSlicer History



- 1997: Slicer started as a research project between the Surgical Planning Lab (Harvard) and the CSAIL (MIT)
- 2012: Multi-institution effort to share the latest advances in image analysis with clinicians and scientists



NA-MIC and NAC



National Alliance for Medical Image Computing

A National Center for Biomedical Computing
Funded under the NIH Roadmap Initiative

Google Custom Search Search

NA-MIC Wiki

General

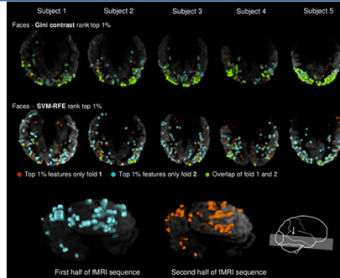
- Overview
- Organization
- Contact Us

Center Components


- Algorithms
- Engineering
- Driving Biological Projects
- Collaboration Grants

Resources

- Publication DB
- Image Gallery
- Downloads
- Service
- Training
- Dissemination
- Events
- Links



Detecting Stable Distributed Patterns of Brain Activation using Gini Contrast [Read more...](#)



1 of 23 Photos

The National Alliance for Medical Image Computing (NA-MIC) is a multi-institutional, interdisciplinary team of computer scientists, software engineers, and medical investigators who develop computational tools for the analysis and visualization of medical image data. The purpose of the Center is to provide the infrastructure and environment for the development of computational algorithms and open-source technologies, and then oversee the training and dissemination of these tools to the medical research community.

Supported by the National Institutes of Health, [Roadmap Initiative](#).

Information about collaborating with NA-MIC is available [on our wiki](#).



97th Scientific Assembly and Annual Meeting

November 27 - December 2, McCormick Place, Chicago.

[Read more...](#)

[NEWS ARCHIVE](#)



Neuroimage Analysis Center

"understanding the human brain through imaging"

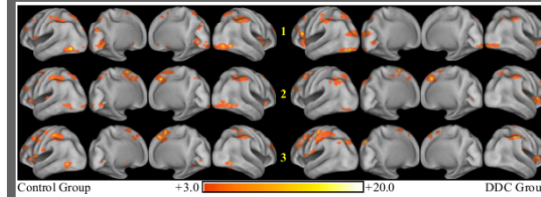
Google Custom Search GO

About the NAC

- Overview
- Organization
- Research Cores
- Collaborations

Resources

- Contact Us
- Publication DB
- Image Gallery
- Downloads
- Training Materials
- Web Archive



State-space Models of Mental Processes from fMRI

Spatial Activity Maps. The average t-score maps of the two groups (voxel-wise group average divided by group std. dev.) are displayed on an inflated brain-surface (left lateral-posterior, left medial-posterior, right medial-posterior and right lateral-posterior). Each row shows the maps for one phase of the task and values 1-3 have been masked out for clarity.

[More...](#)

[Featured Image Archive](#)

The Neuroimage Analysis Center (NAC) develops image processing and analysis techniques for basic and clinical neurosciences. The NAC research approach emphasizes both specific core technologies and collaborative application projects. The activities of the NAC are centered at the Harvard Medical School and the Surgical Planning Laboratory at the Brigham and Women's Hospital in Boston, with collaborators throughout the United States and the rest of the world.

The NAC is a major research center supported by the National Center for Research Resources (NCRR), a component of the National Institutes of Health.



P.I. Ron Kikinis, M.D.




Slicer: Behind the scenes

</

Slicer is built every night on Windows, Mac and Linux platforms



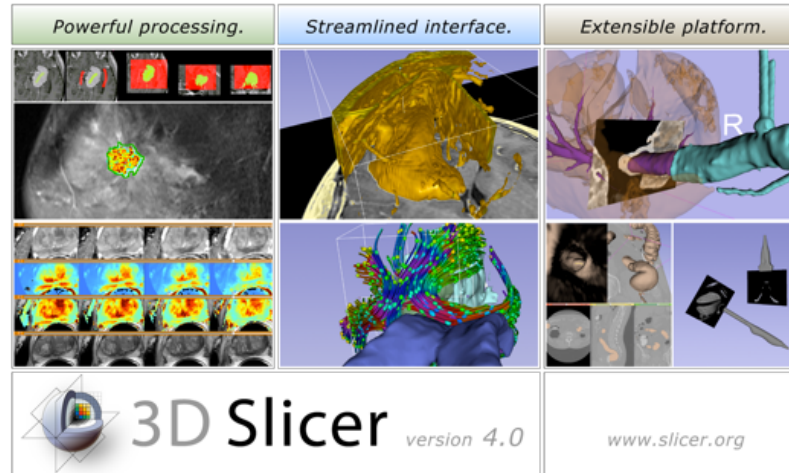
Slicer Training



- Hands-on training workshops at national and international venues
- >2,000 clinicians, clinical researchers and scientists trained since 2005

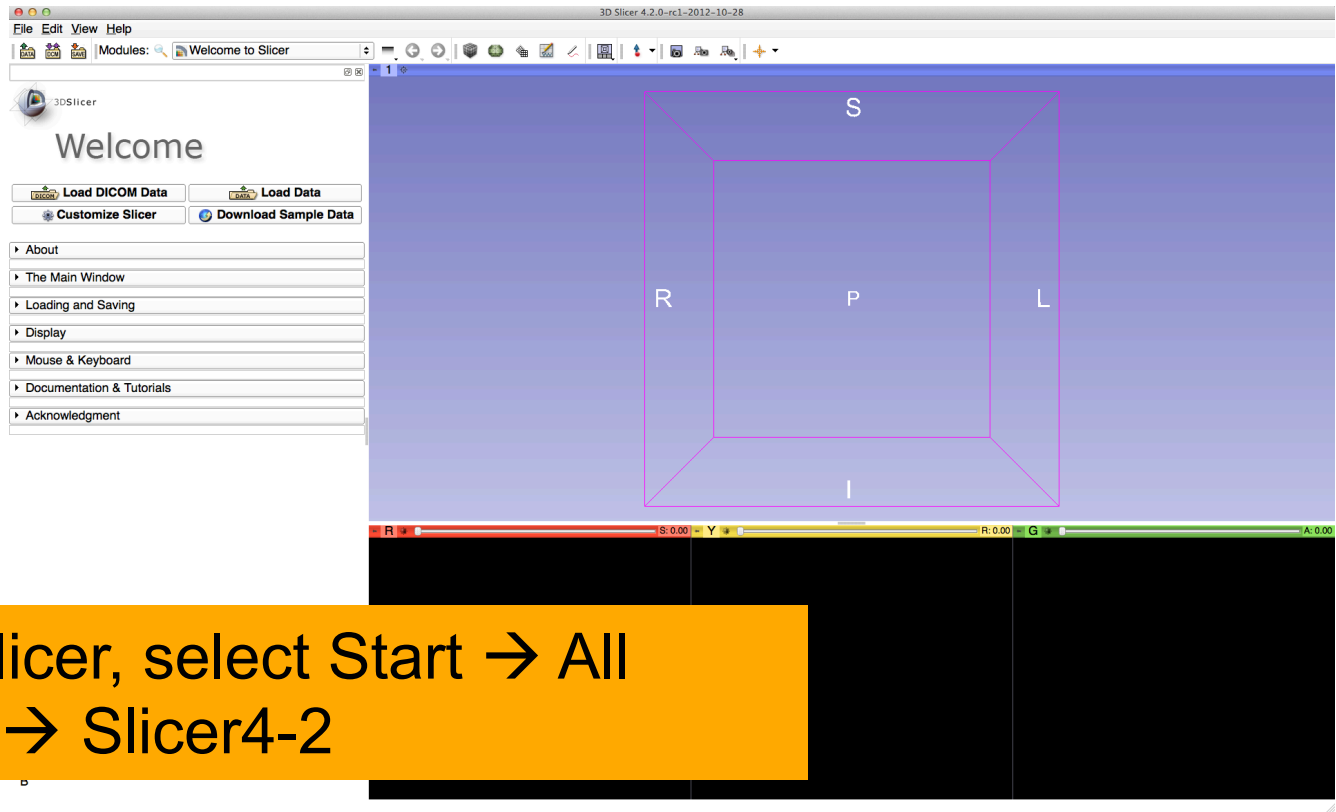


3DSlicer version 4.2





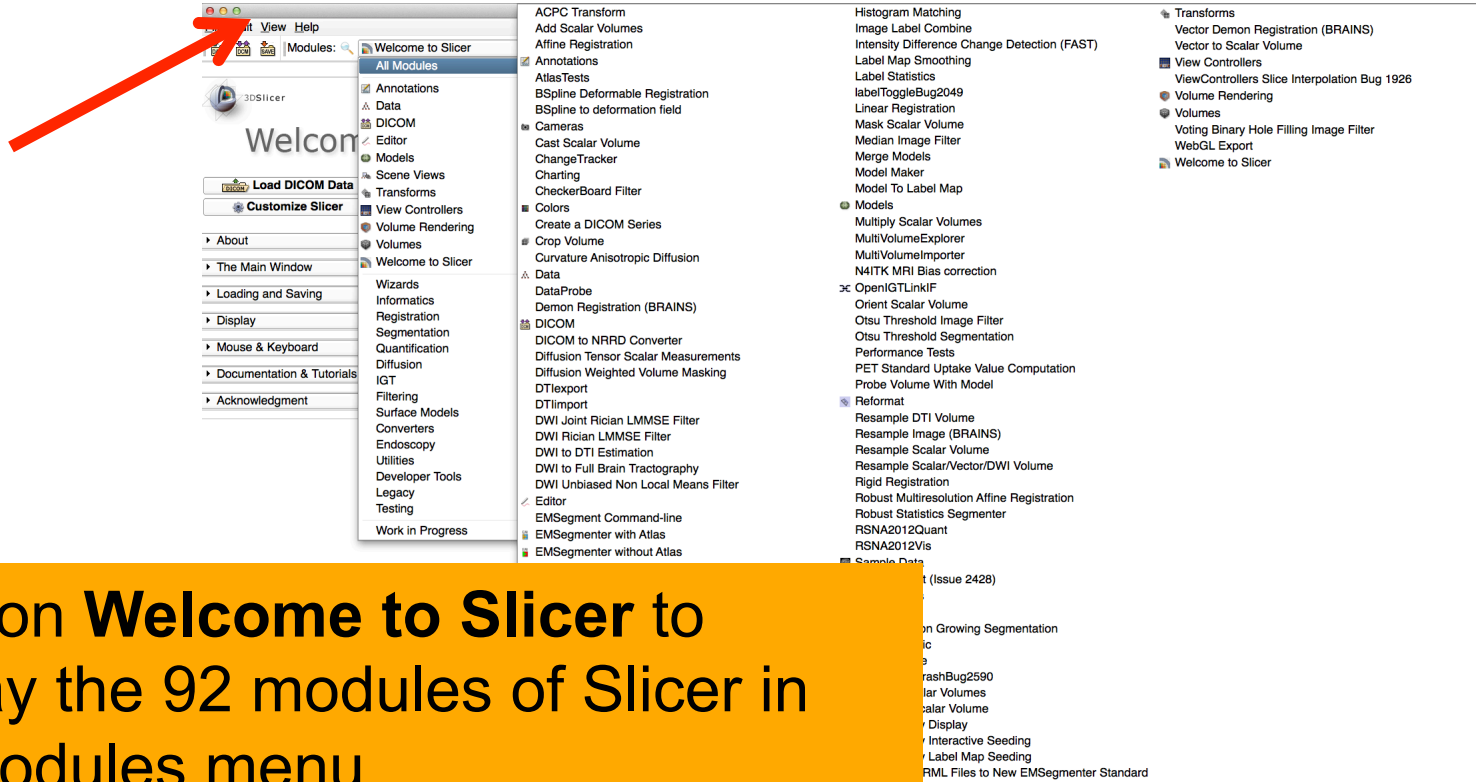
Welcome to Slicer4



To start Slicer, select Start → All Programs → Slicer4-2



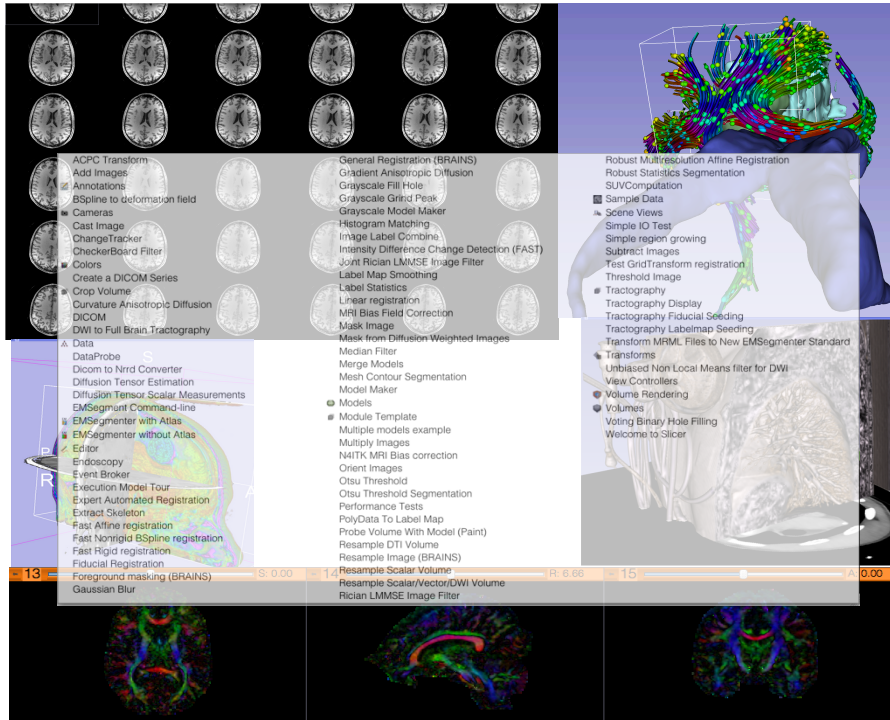
Welcome to Slicer4.2



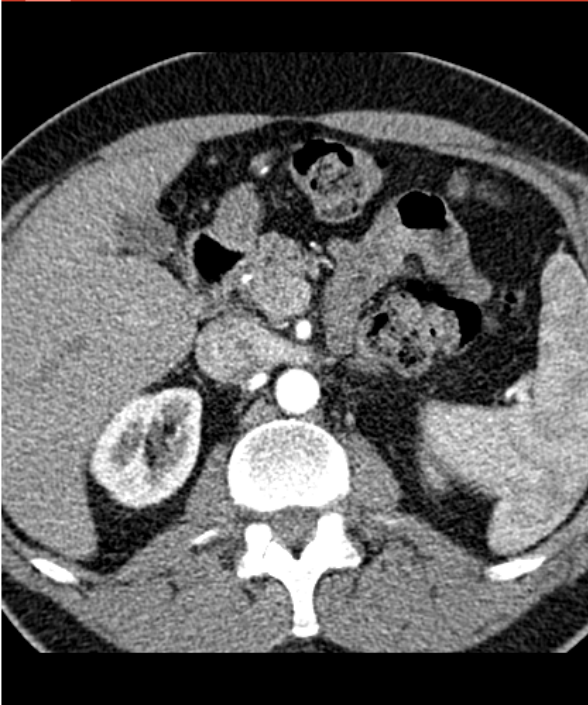
Click on **Welcome to Slicer** to display the 92 modules of Slicer in the Modules menu



Welcome to Slicer4



Slicer4.2 contains more than 90 modules for image segmentation, registration and 3D visualization of medical imaging data



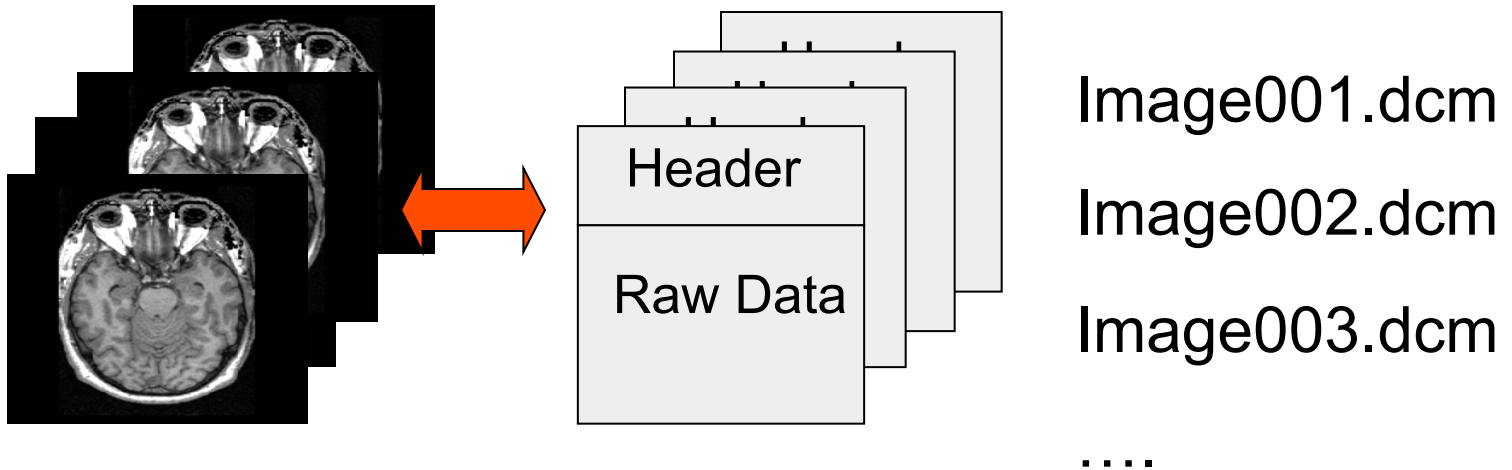
Part 1:

Loading a DICOM Volume



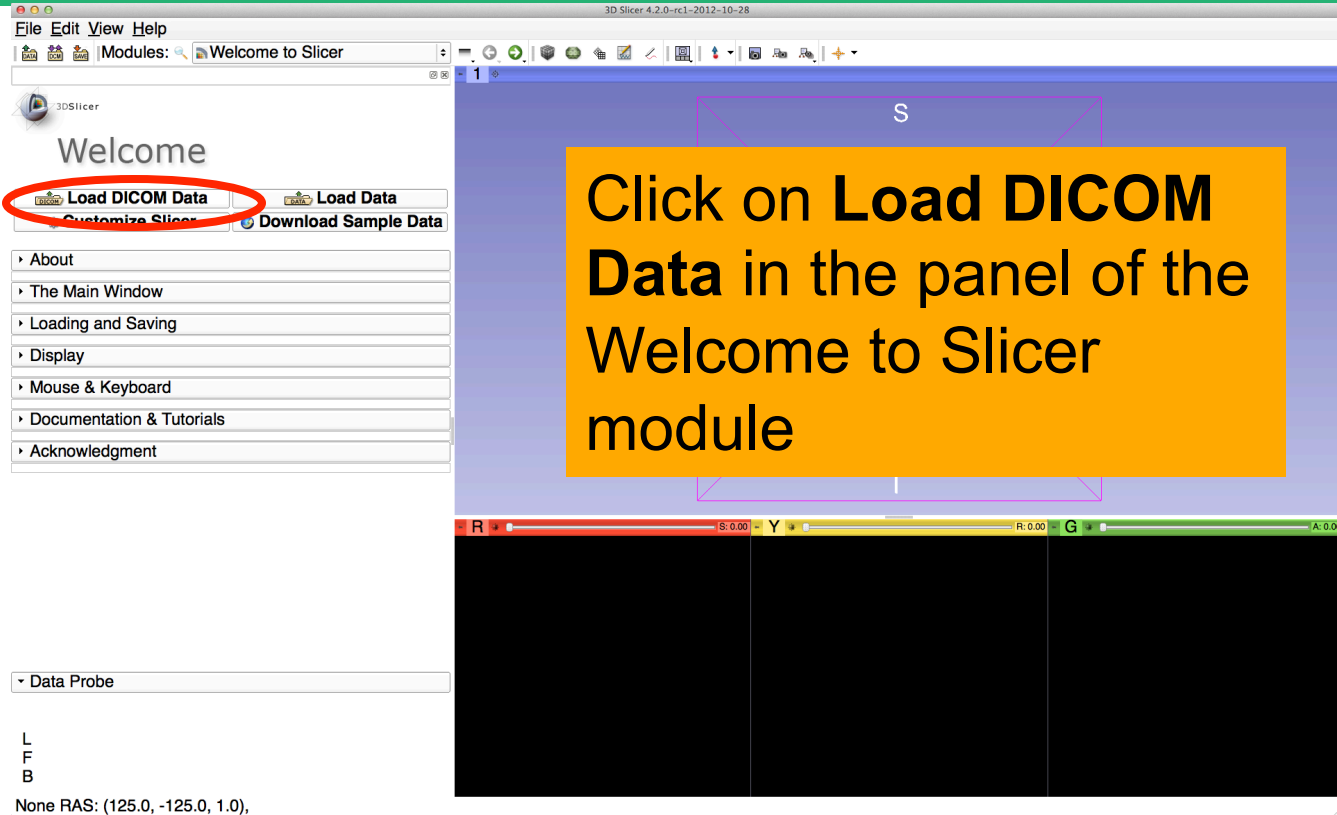
The DICOM 3.0 File Format

Most radiological imaging equipment produce images in DICOM file format (‘.dcm files’)



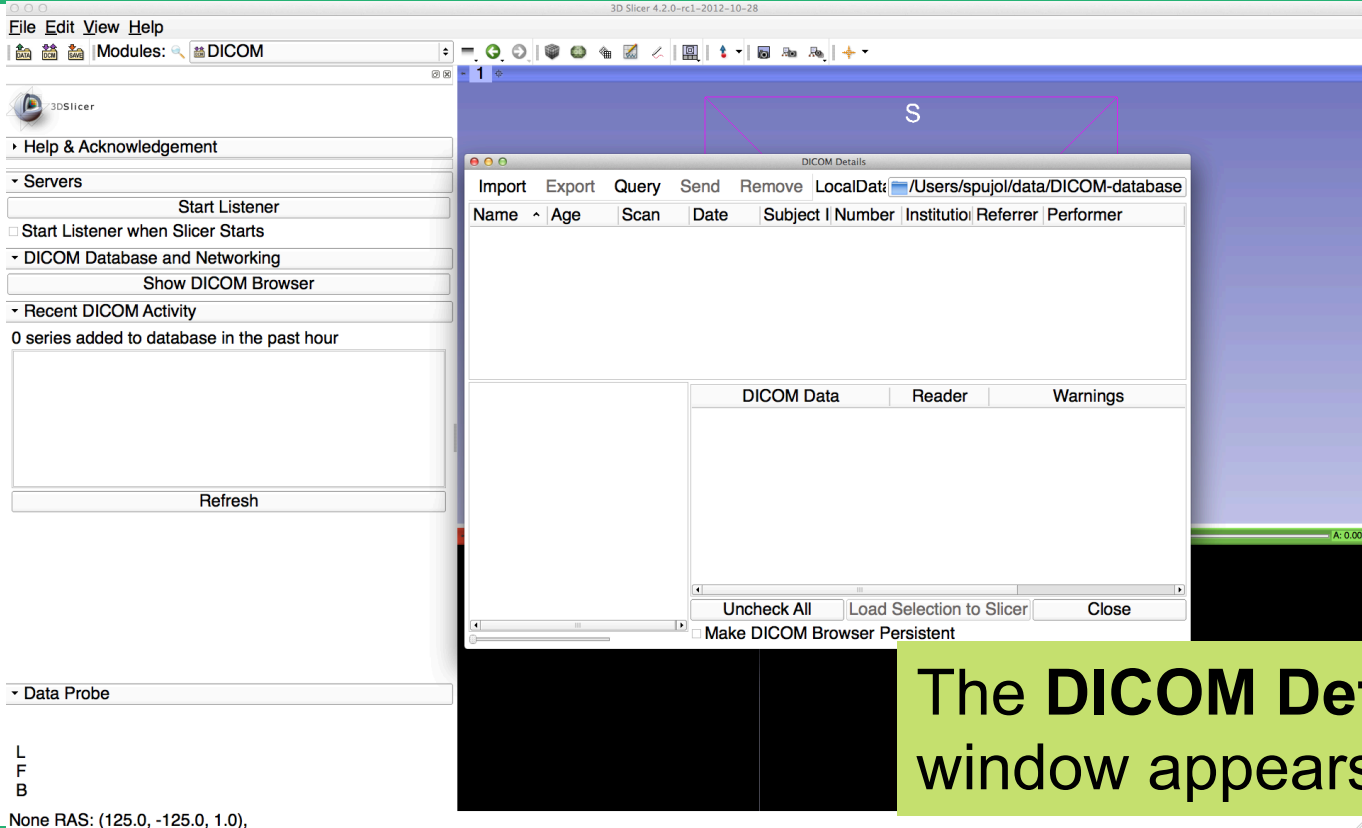


Loading a DICOM volume





Loading a DICOM volume

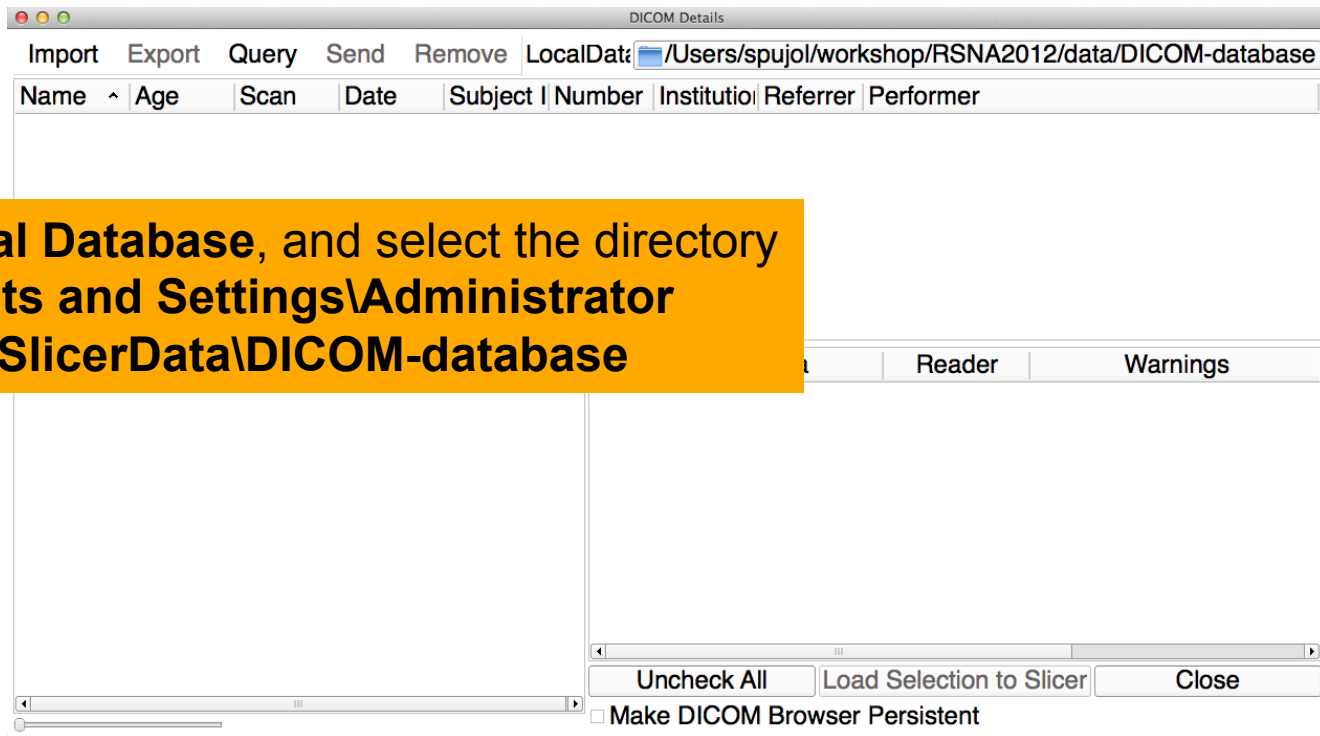


The DICOM Details window appears



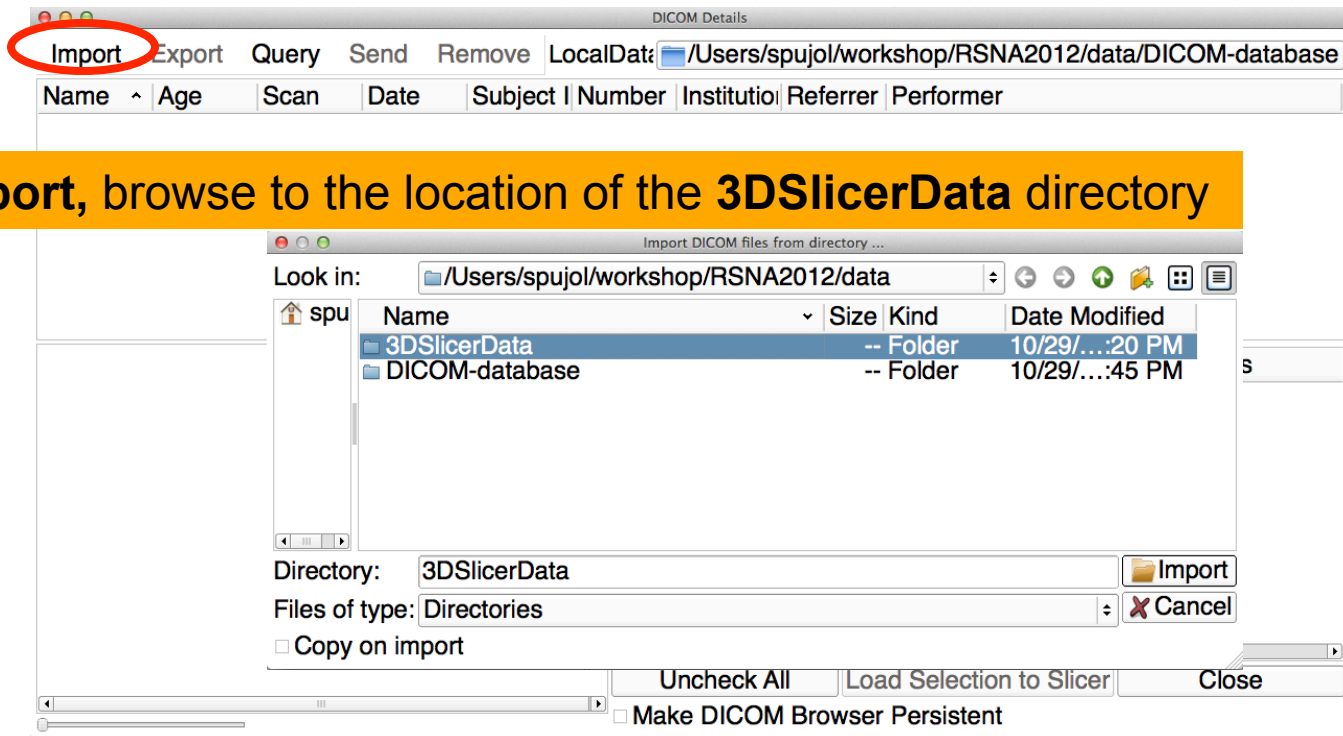
Loading a DICOM volume

Click on **Local Database**, and select the directory
**C:\Documents and Settings\Administrator
\Desktop\3DSlicerData\DICOM-database**



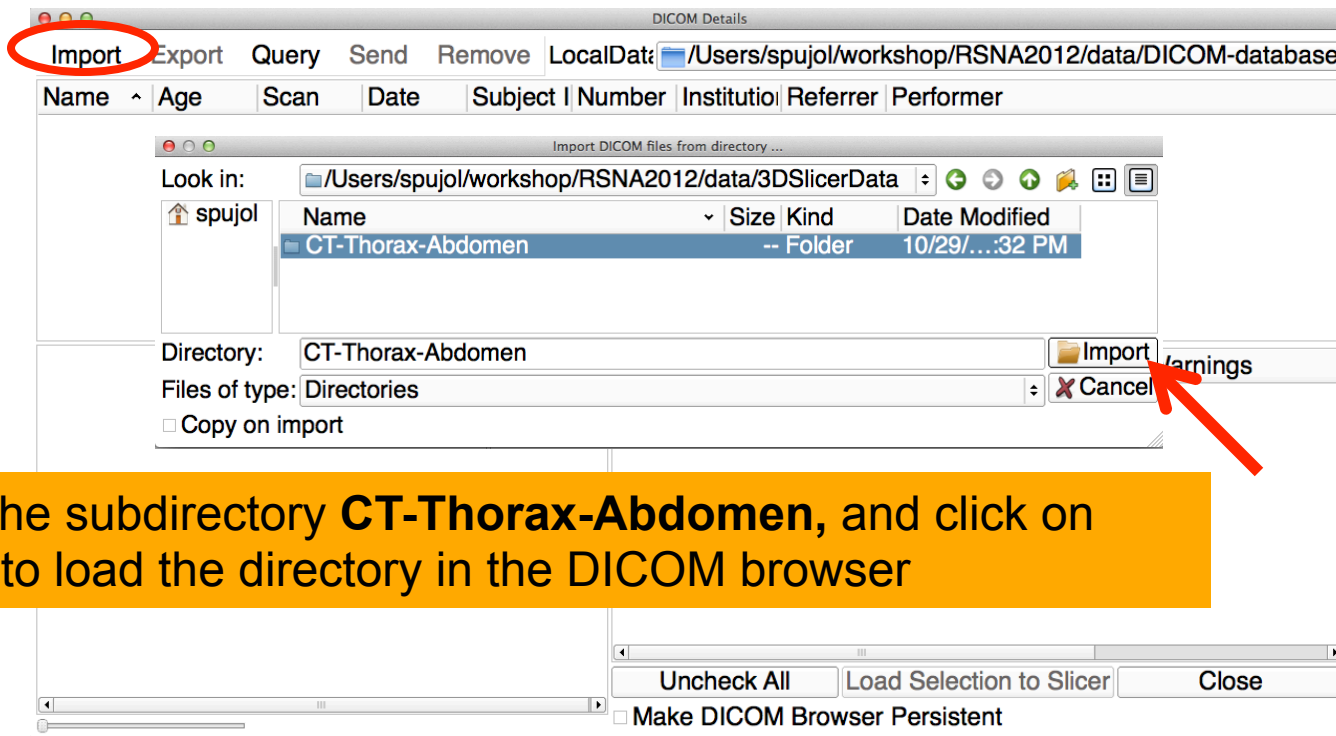


Loading a DICOM volume





Loading a DICOM volume



Select the subdirectory **CT-Thorax-Abdomen**, and click on **Import** to load the directory in the DICOM browser



Loading a DICOM volume

The screenshot shows a window titled "DICOM Details" with a menu bar (Import, Export, Query, Send, Remove) and a local data path: /Users/spujol/workshop/RSNA2012/data/DICOM-database. Below is a table of DICOM data:

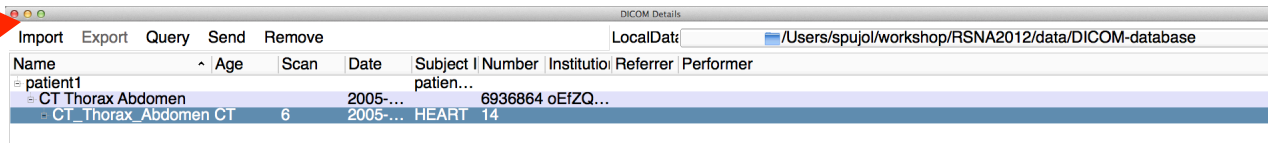
Name	Age	Scan	Date	Subject	Number	Institution	Referrer	Performer
patient1				patien...				
CT Thorax Abdomen			2005-...		6936864	oEfZQ...		
CT_Thorax_Abdomen CT		6	2005-...	HEART	14			

A red arrow points to the "CT_Thorax_Abdomen CT" entry. Below the table are tabs for "DICOM Data", "Reader", and "Warnings". At the bottom, there are buttons for "Uncheck All", "Load Selection to Slicer", and "Close", along with a checkbox for "Make DICOM Browser Persistent".

The patient1 DICOM dataset appears in the DICOM browser. Click on 'patient1' to display the file hierarchy, select the DICOM volume **CT_Thorax_Abdomen**

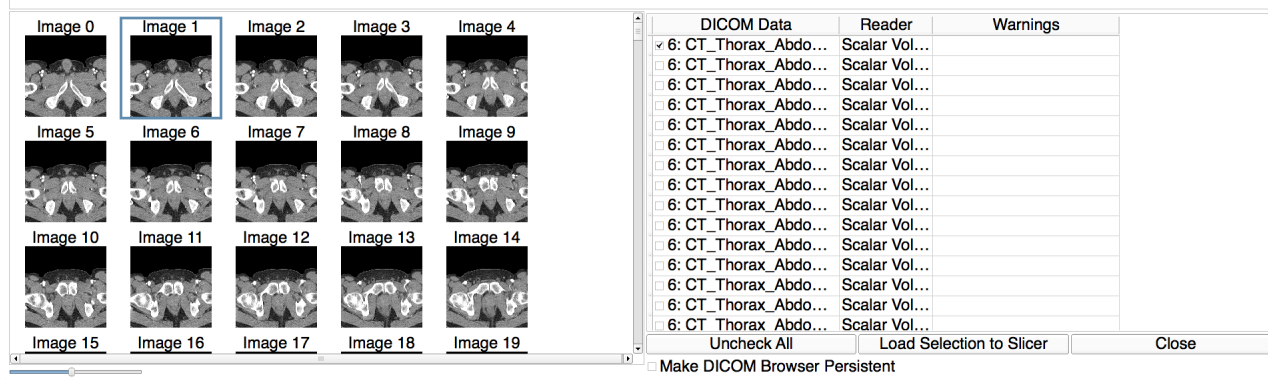


Loading a DICOM volume



Click to expand the DICOM Browser window.

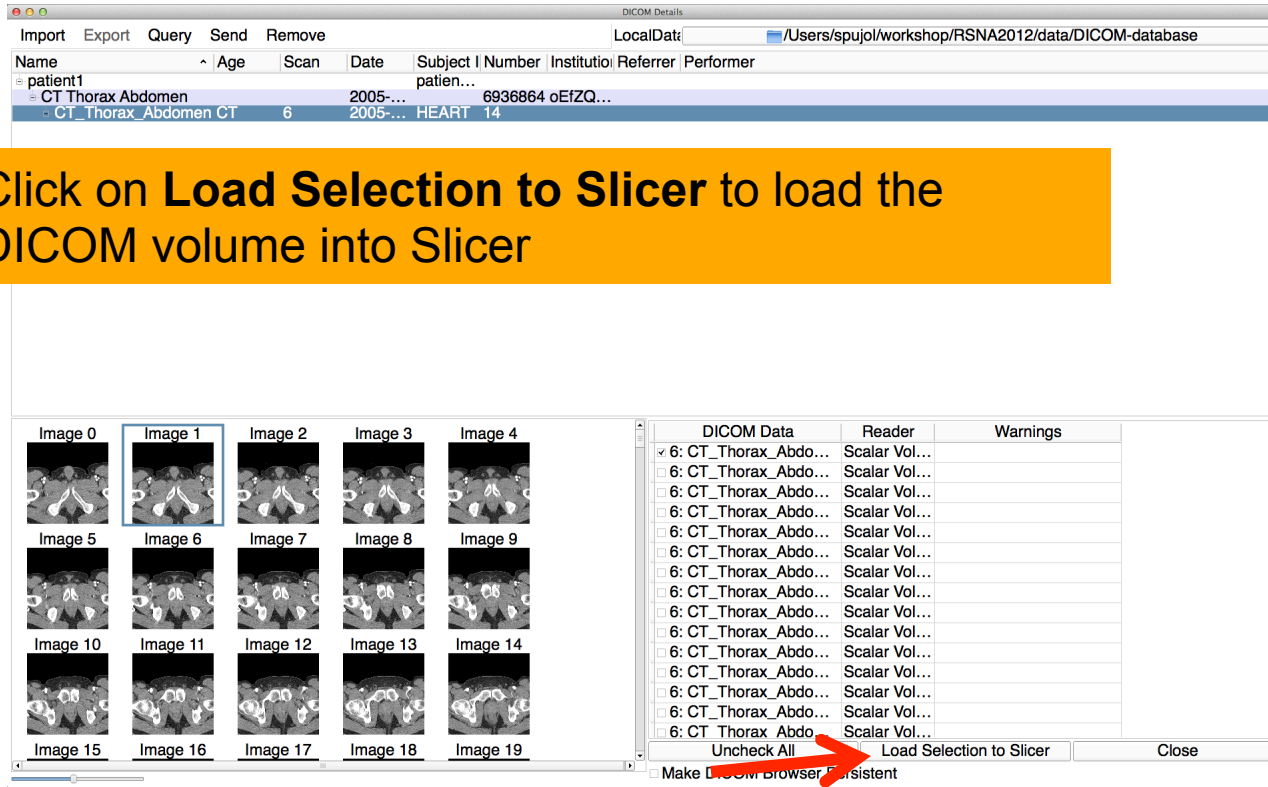
Slicer displays the snapshots of the DICOM images of the **CT_Thorax_Abdomen** dataset





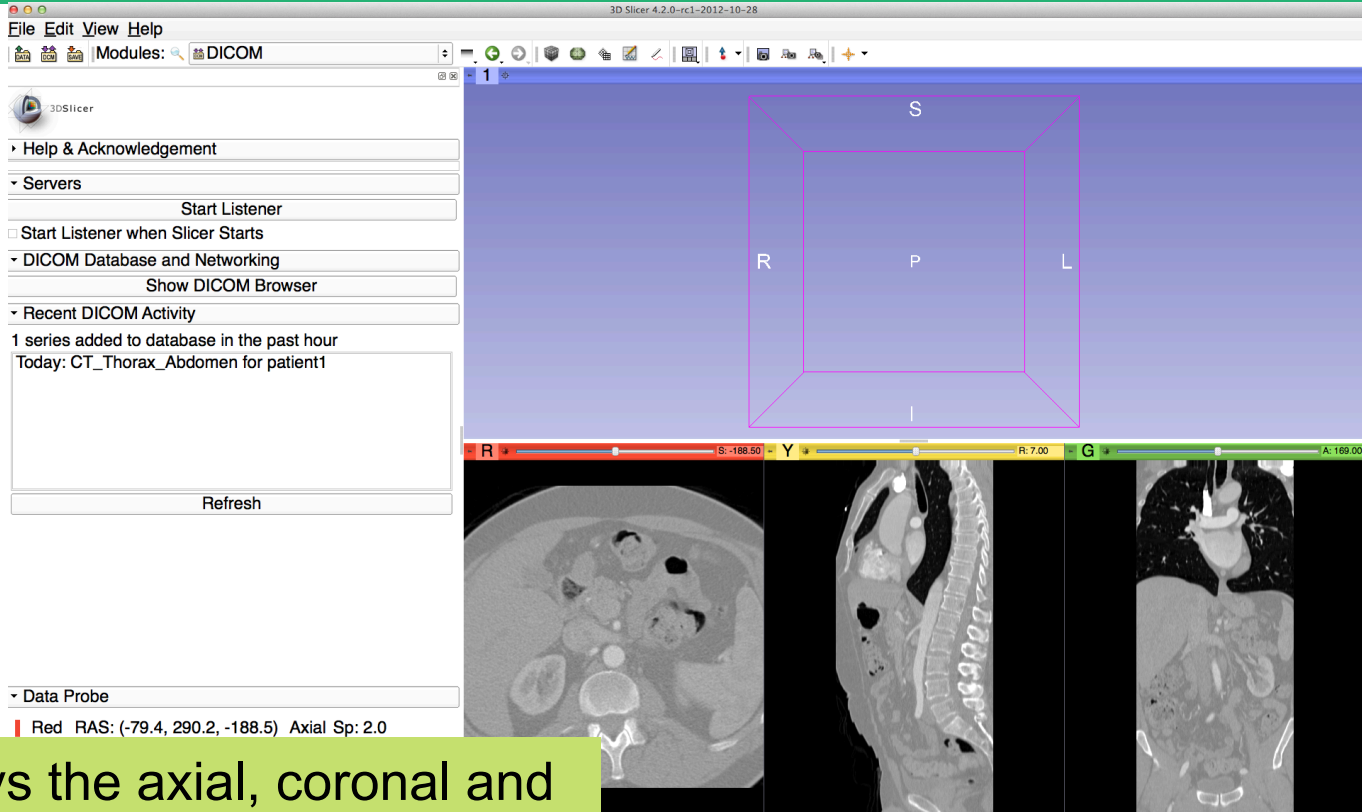
Loading a DICOM volume

Click on **Load Selection to Slicer** to load the DICOM volume into Slicer





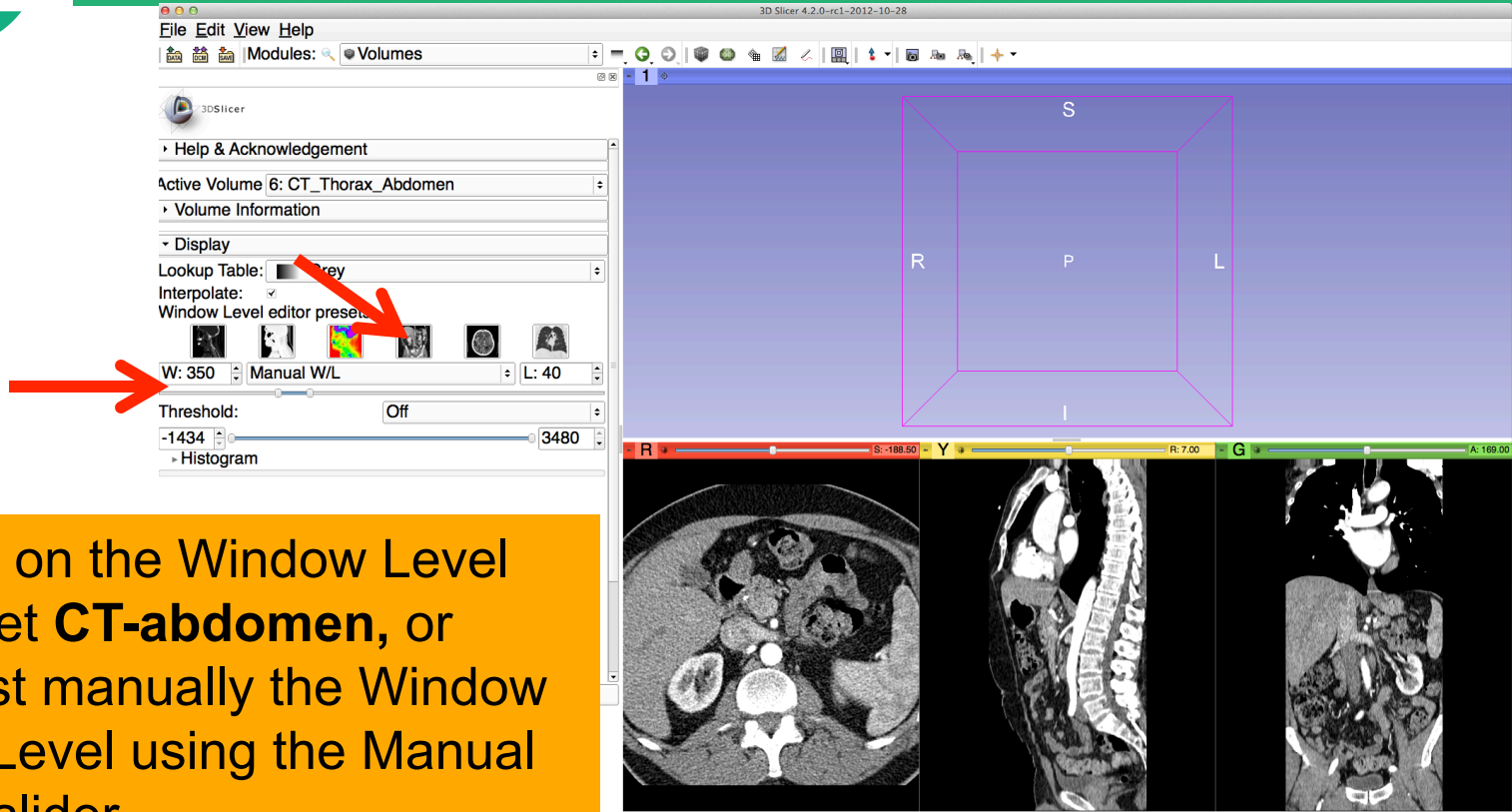
Loading a DICOM volume



Slicer displays the axial, coronal and sagittal slices of the DICOM dataset



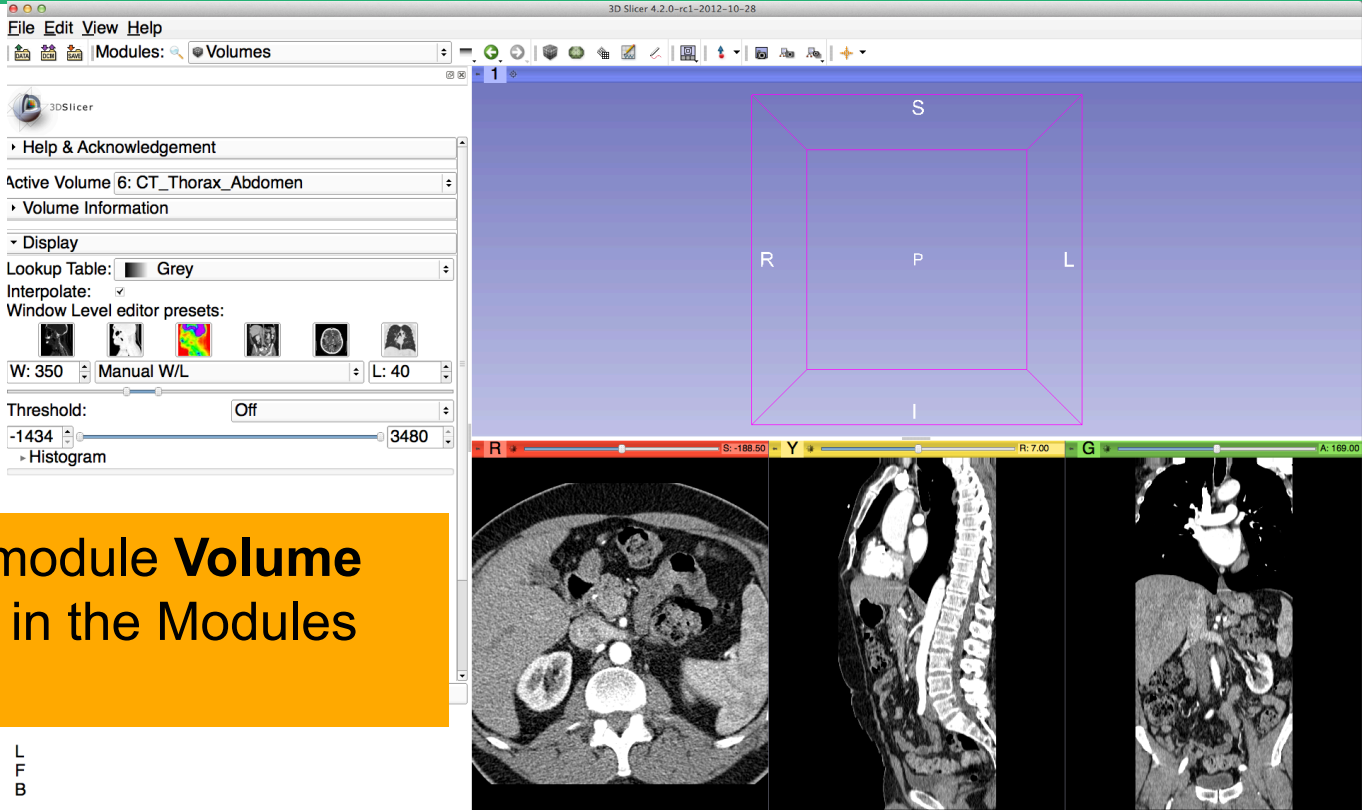
Loading a DICOM volume



Click on the Window Level Preset **CT-abdomen**, or adjust manually the Window and Level using the Manual W/L slider



Loading a DICOM volume



Select the module **Volume Rendering** in the Modules Menu

L
F
B

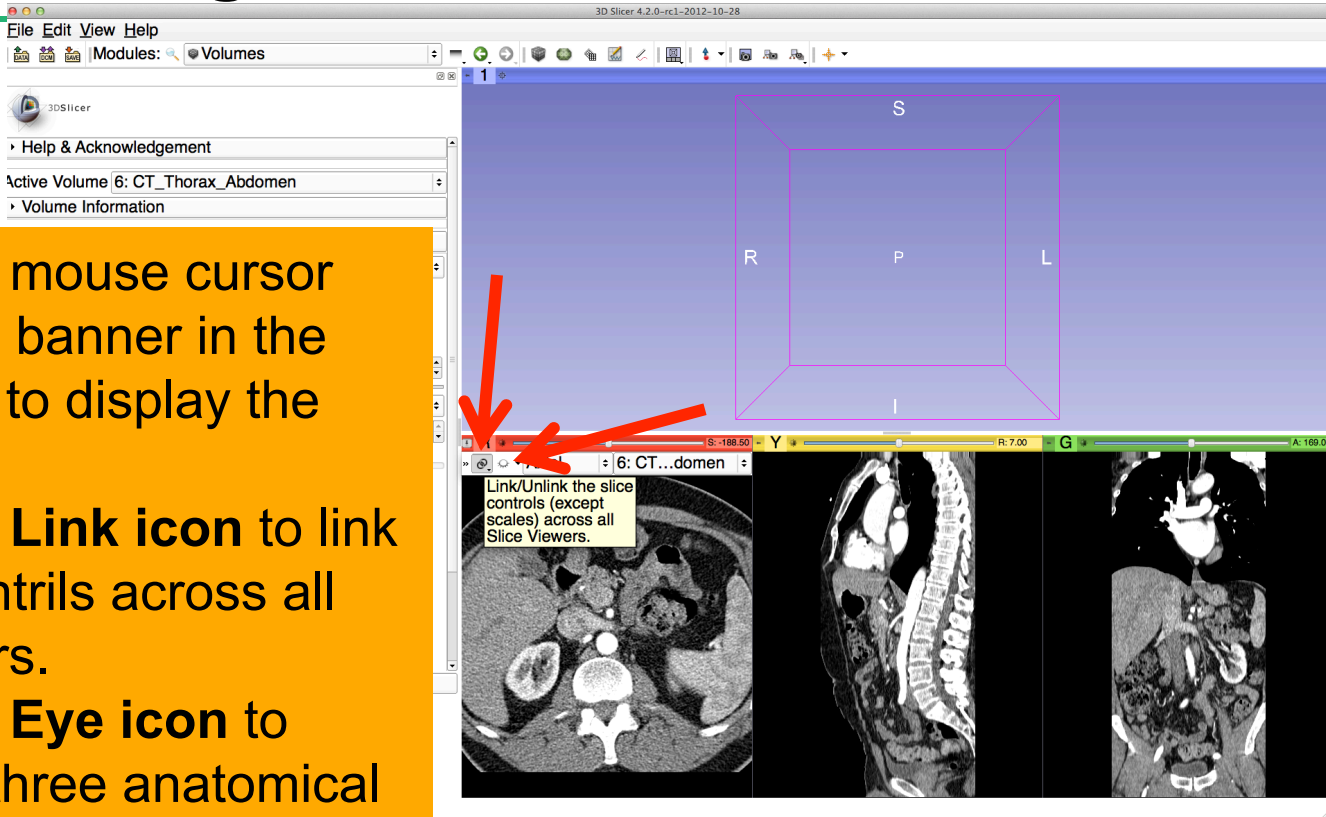


Loading a DICOM volume

Position the mouse cursor over the red banner in the Red Viewer to display the slice menu.

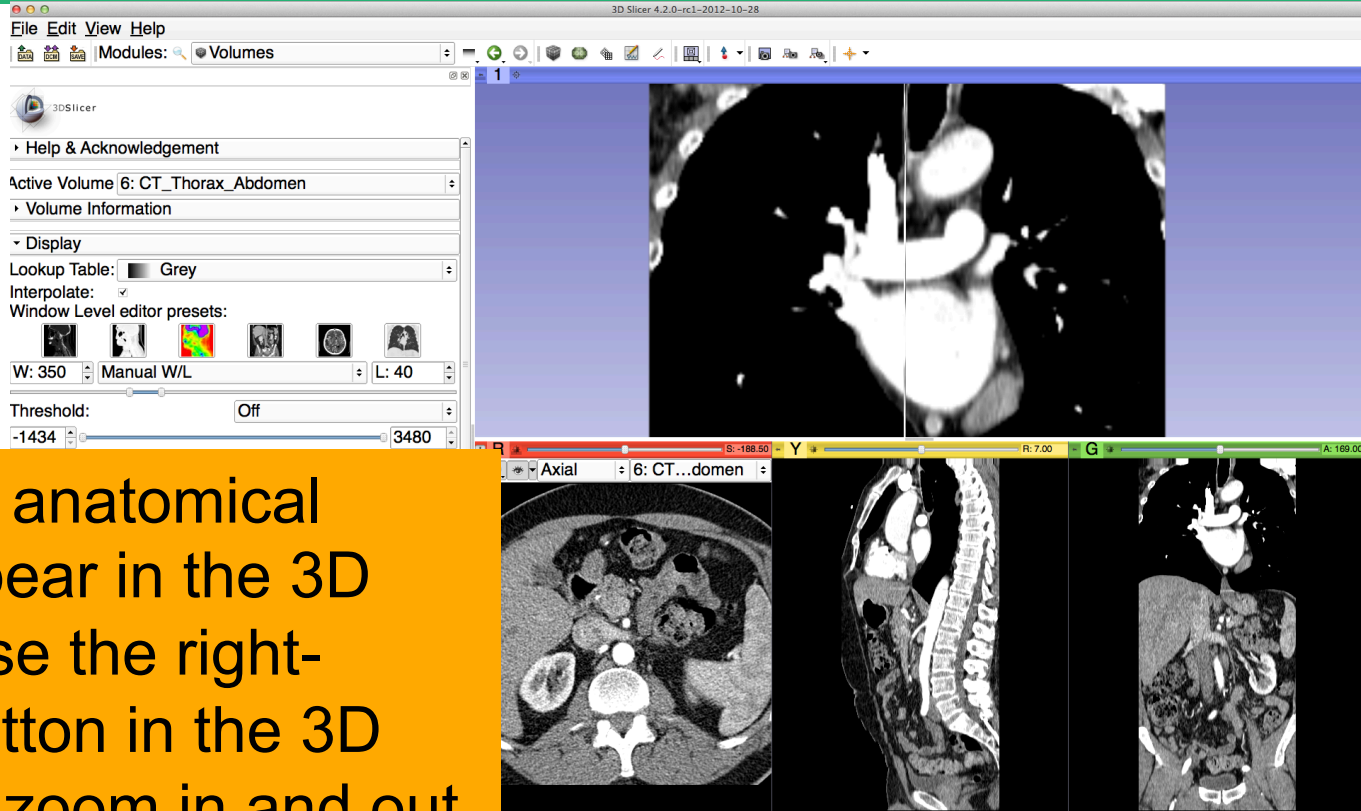
Click on the **Link icon** to link the slice controls across all Slice Viewers.

Click on the **Eye icon** to display the three anatomical slices in the 3D Viewer





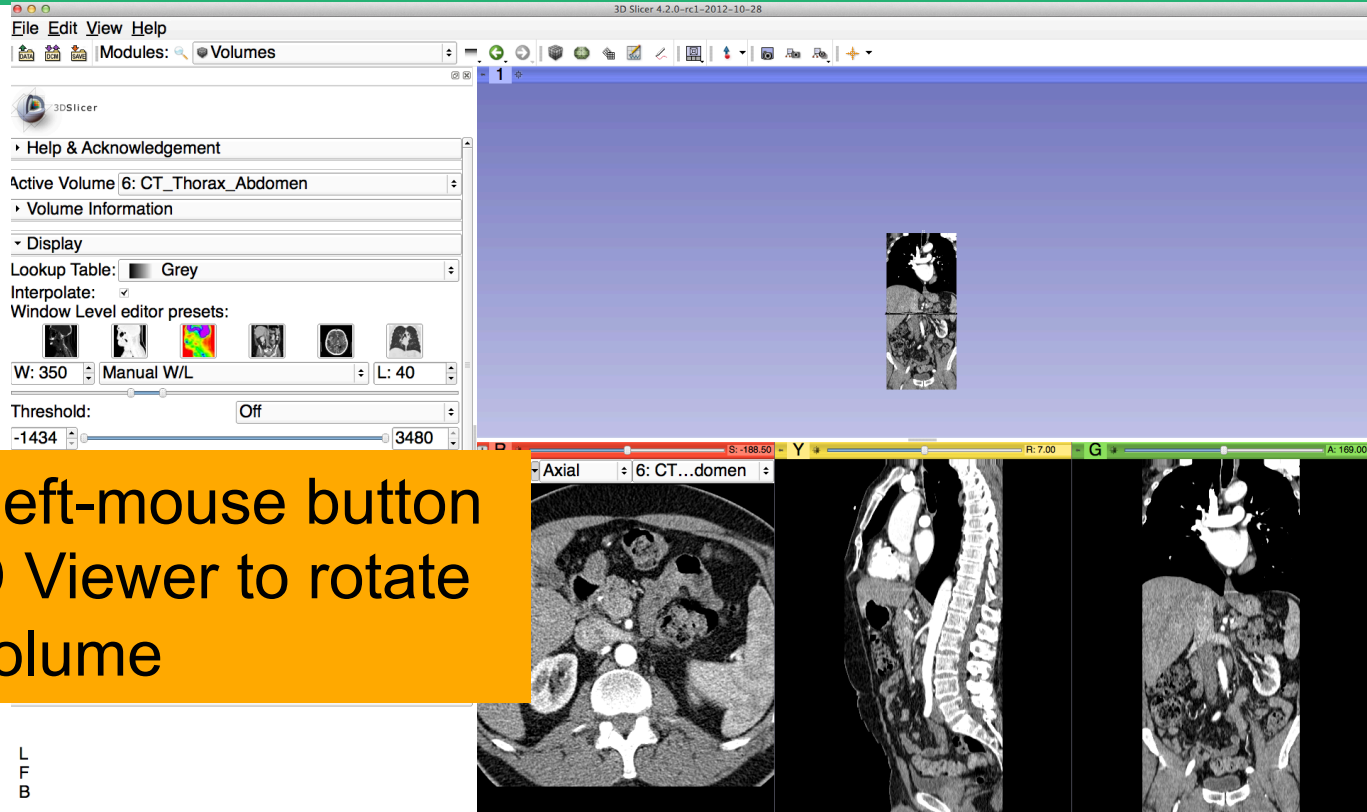
Loading a DICOM volume



The three anatomical slices appear in the 3D viewer. Use the right-mouse button in the 3D Viewer to zoom in and out



Loading a DICOM volume

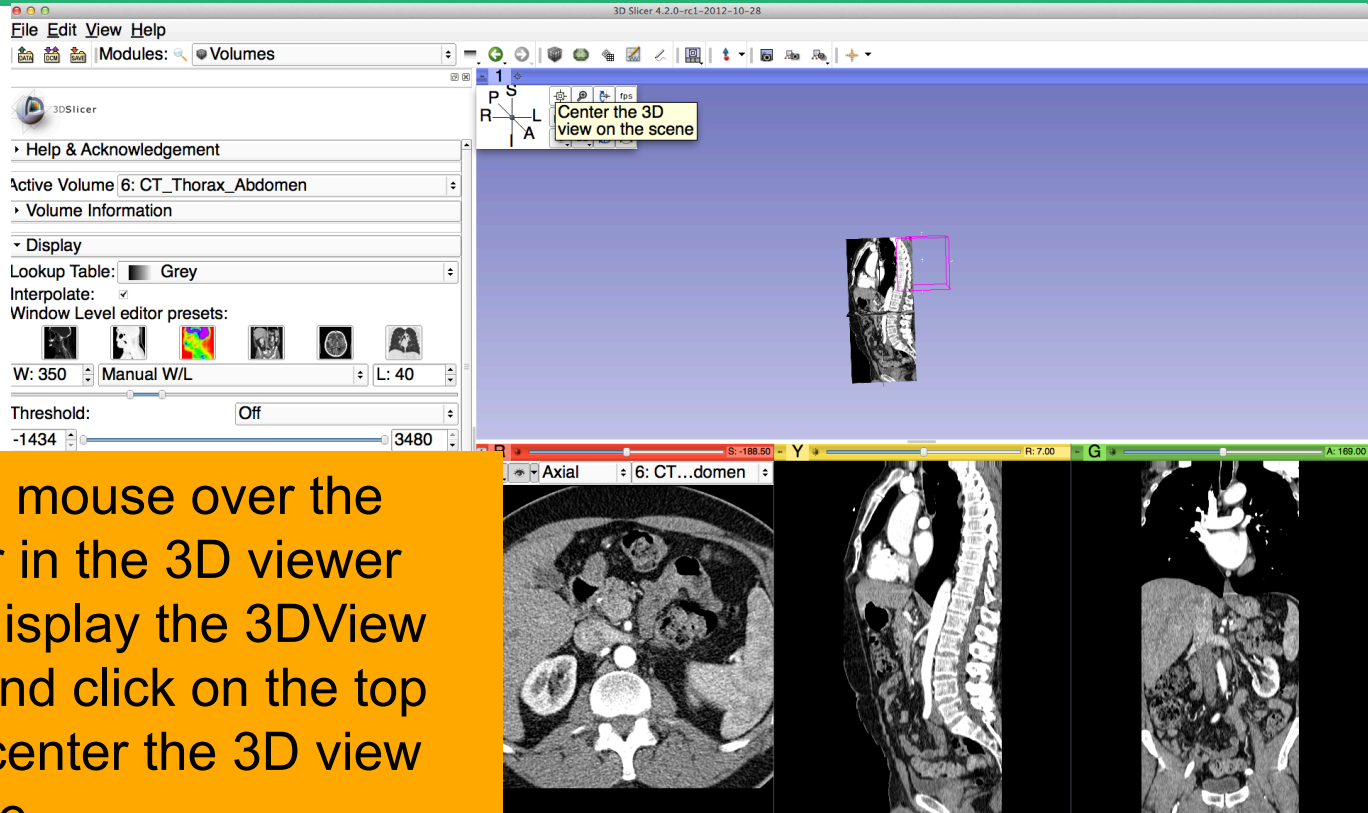


Use the left-mouse button
in the 3D Viewer to rotate
the 3D volume

L
F
B



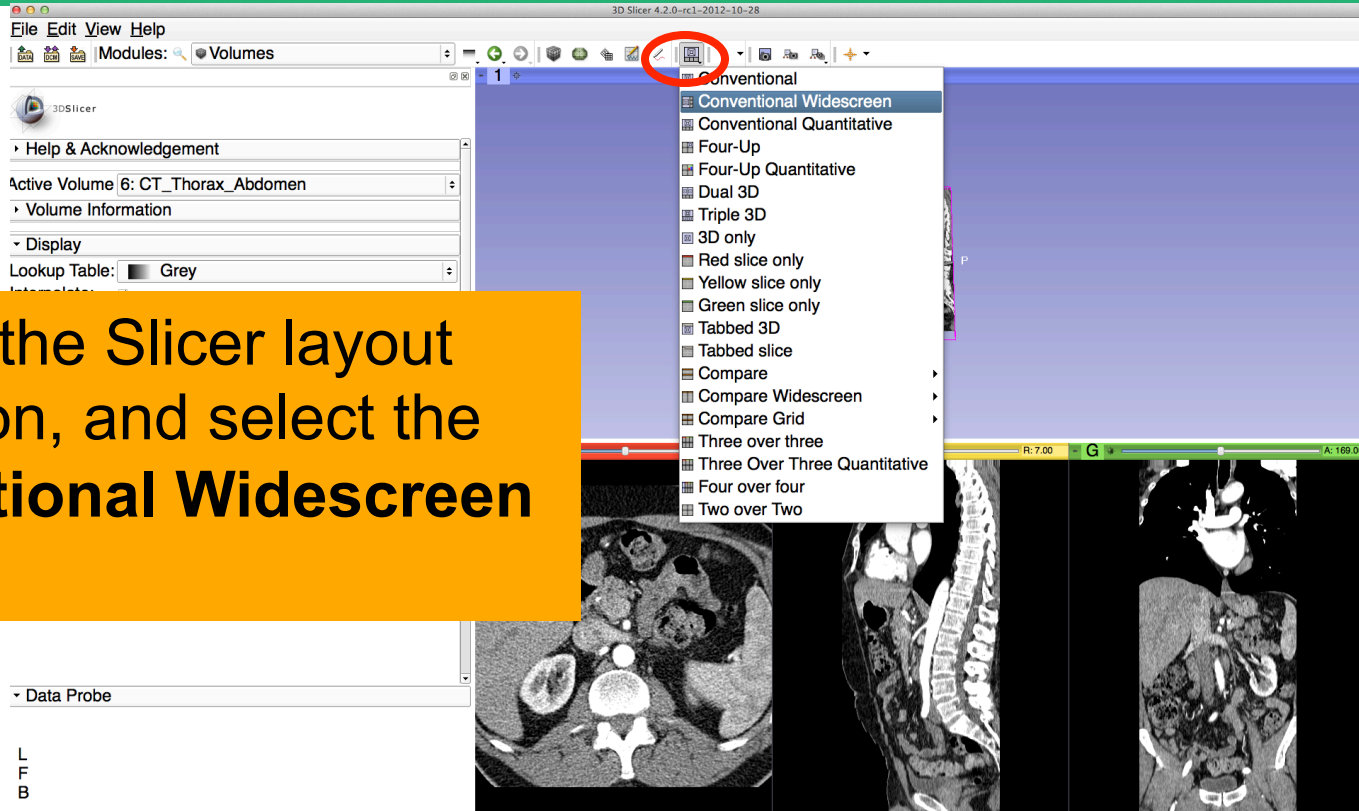
Loading a DICOM volume



Position the mouse over the blue banner in the 3D viewer window to display the 3DView controller, and click on the top left icon to center the 3D view on the scene



Loading a DICOM volume




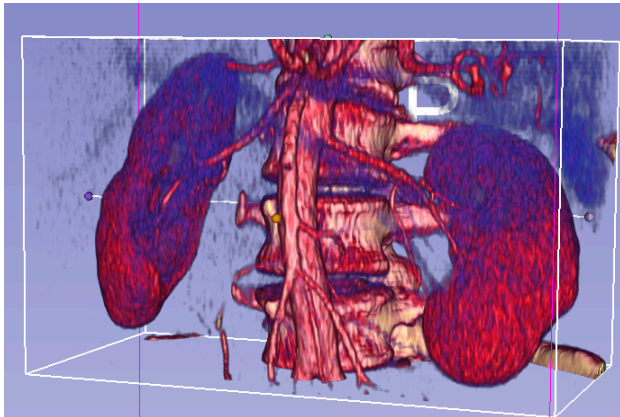
Click on the Slicer layout menu icon, and select the **Conventional Widescreen** layout



Loading a DICOM volume

Use the red slice, yellow slice and green slice sliders to slice through the volume in all three anatomical directions





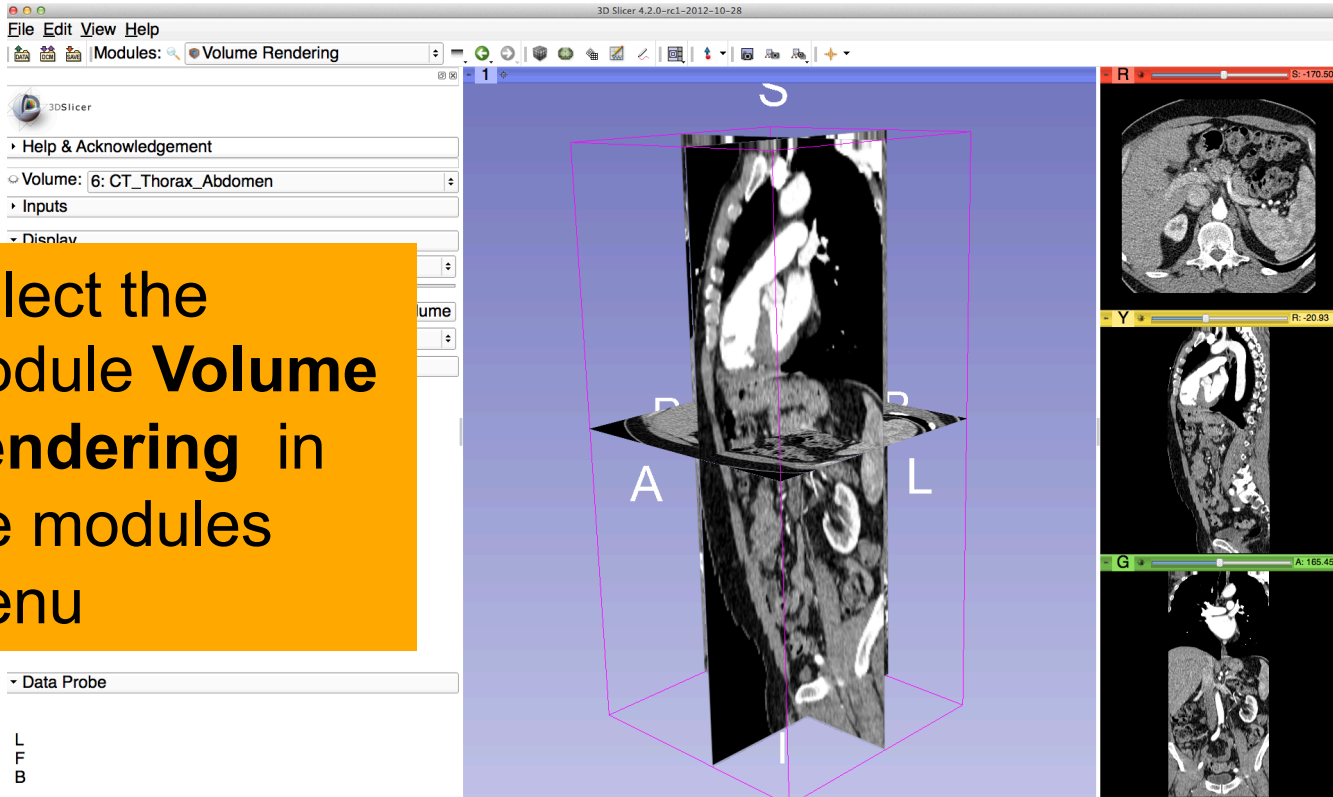
Part 2:

3D Interactive exploration
of thoraco-abdominal CT
data using Volume
Rendering



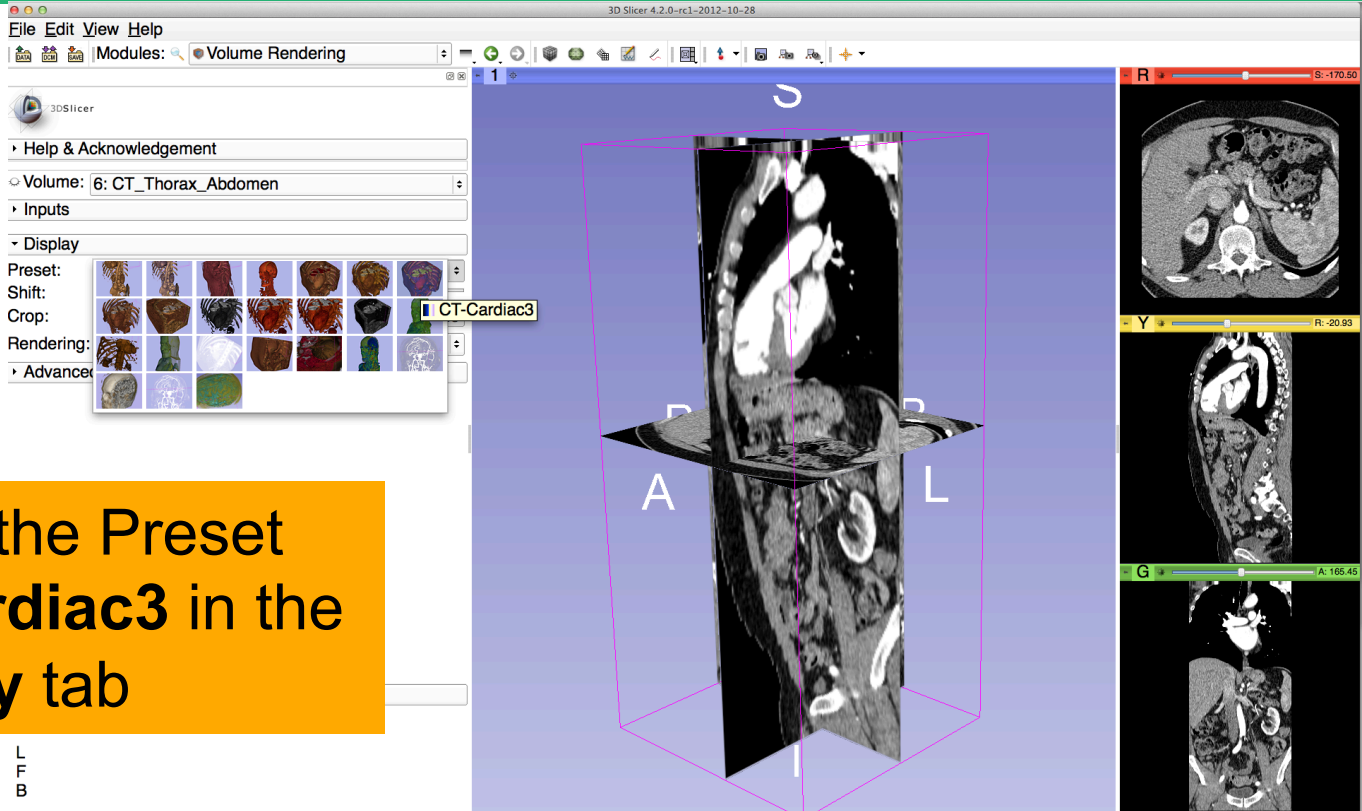
Loading a DICOM volume

Select the
module **Volume
Rendering** in
the modules
menu





Loading a DICOM volume

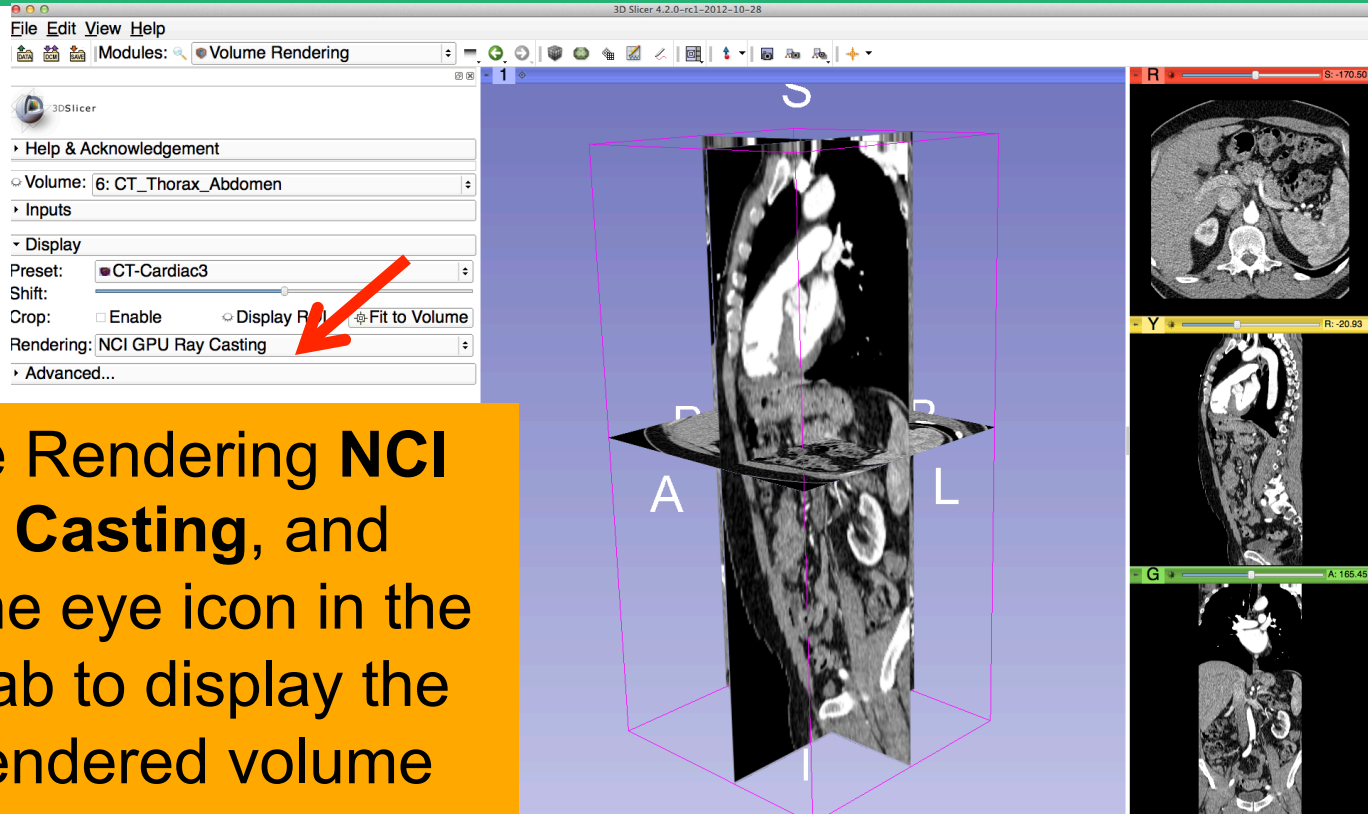


Select the Preset
CT-Cardiac3 in the
Display tab

L
F
B



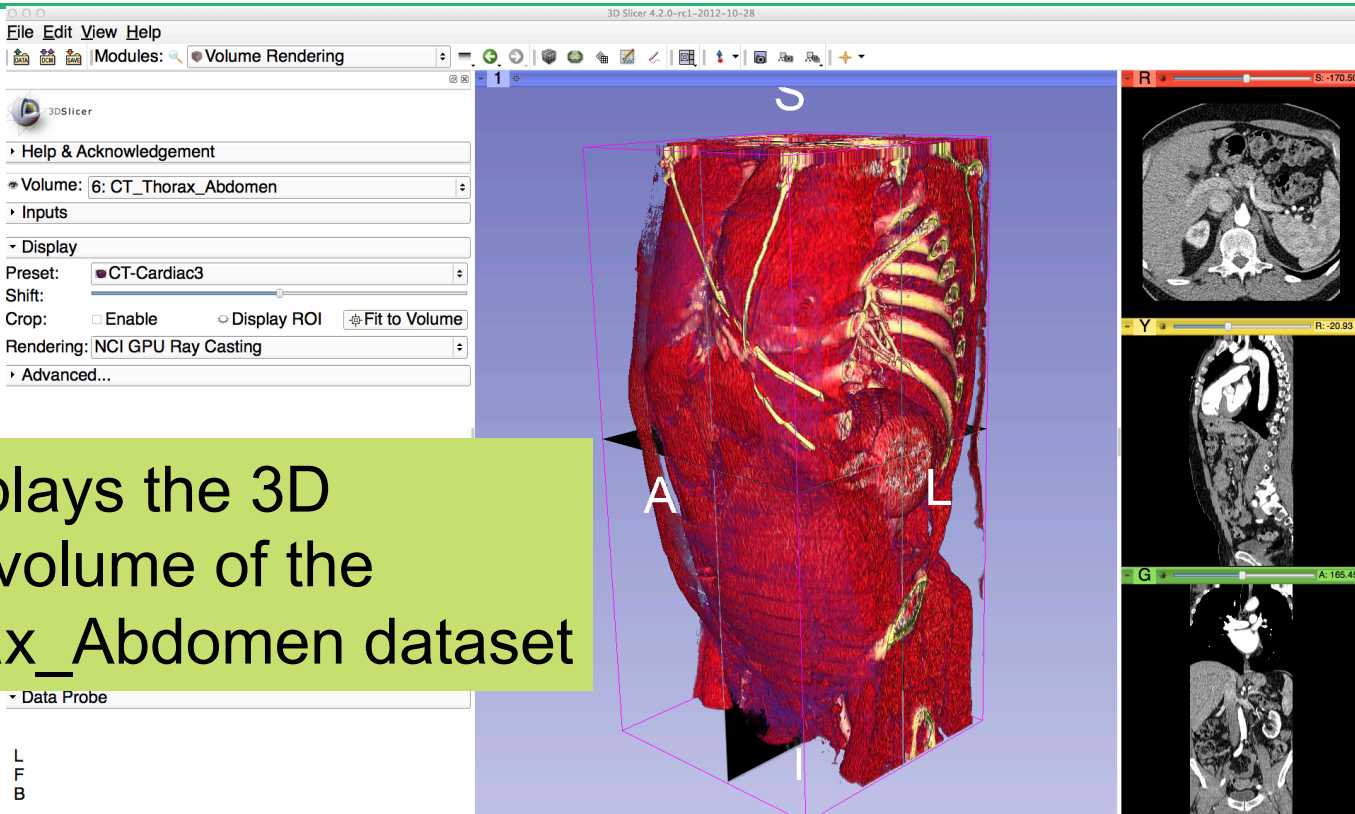
Loading a DICOM volume



Select the Rendering **NCI GPU Ray Casting**, and click on the eye icon in the **Volume** tab to display the Volume rendered volume in the 3D viewer



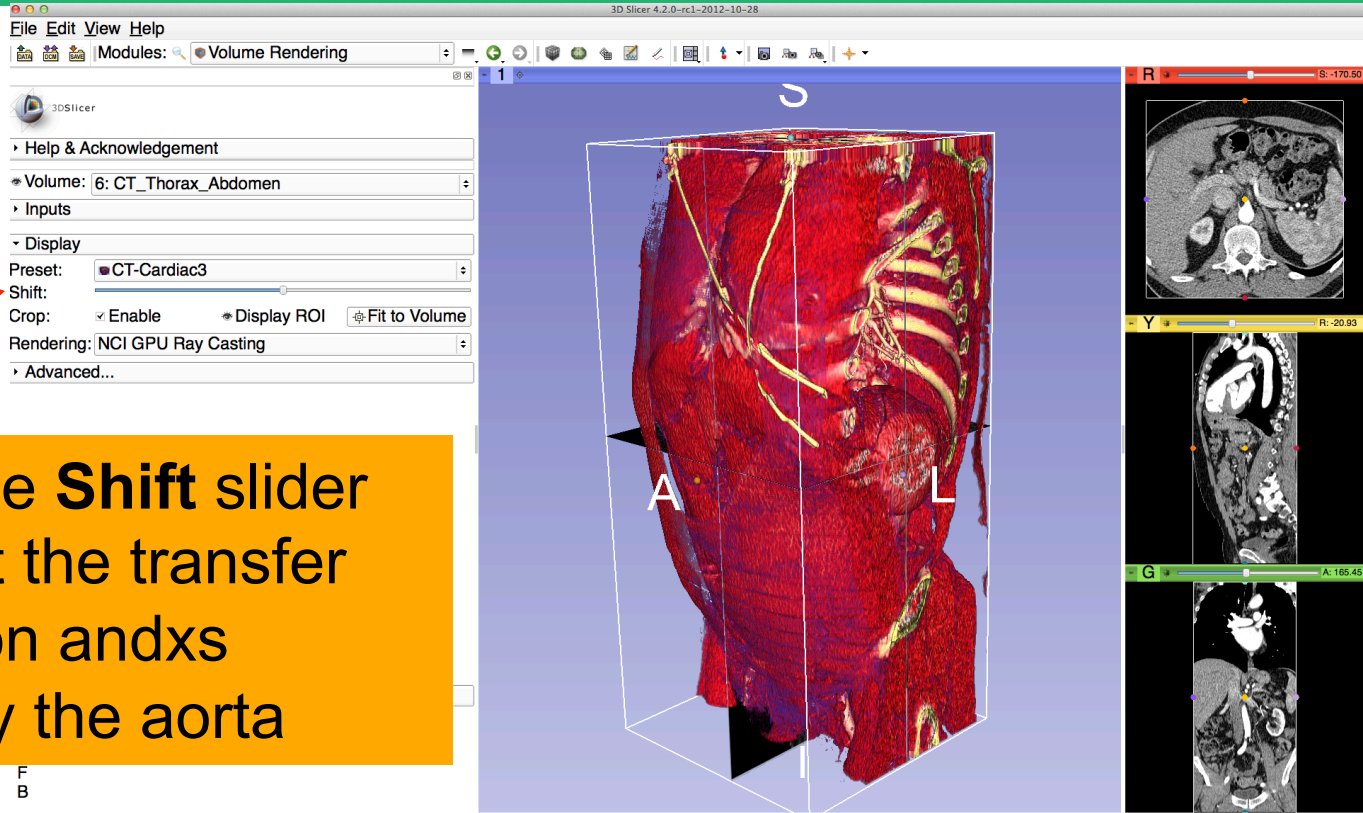
GPU Volume Rendering



Slicer displays the 3D rendered volume of the CT_Thorax_Abdomen dataset



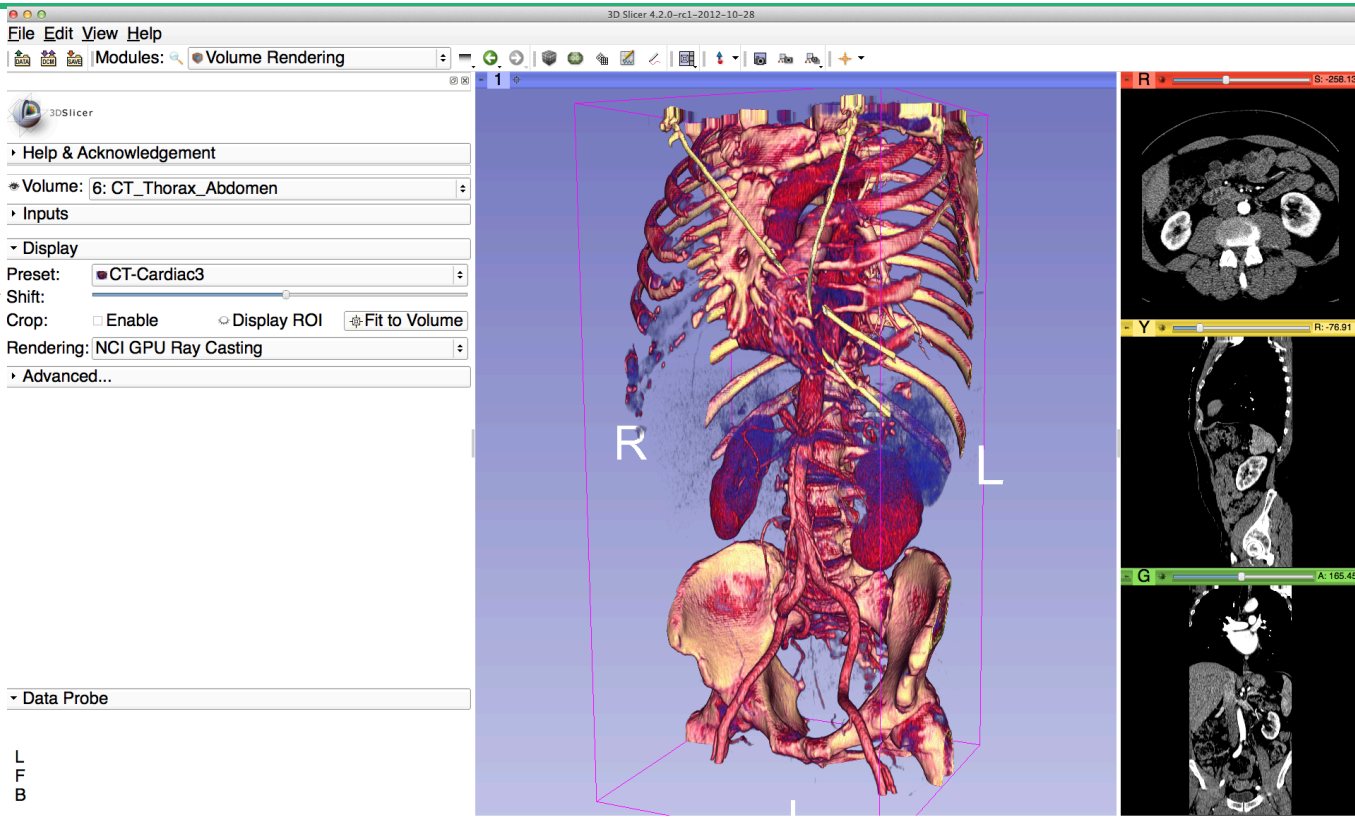
GPU Volume Rendering



Use the **Shift** slider to shift the transfer function and x's display the aorta

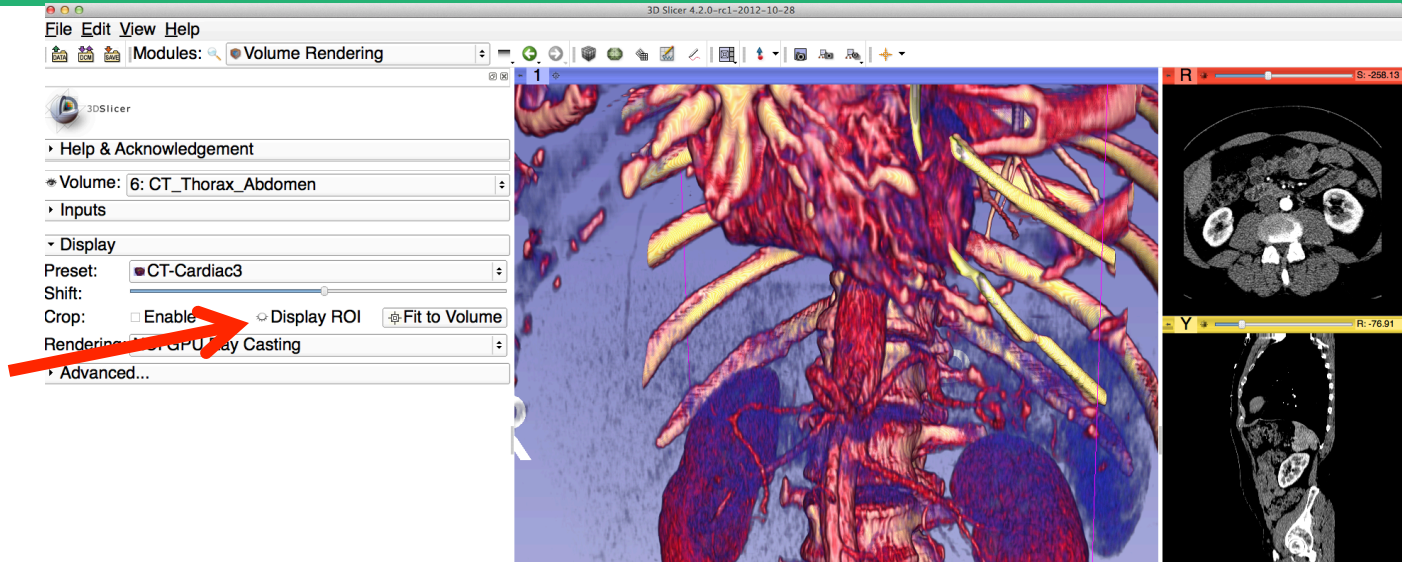


GPU Volume Rendering





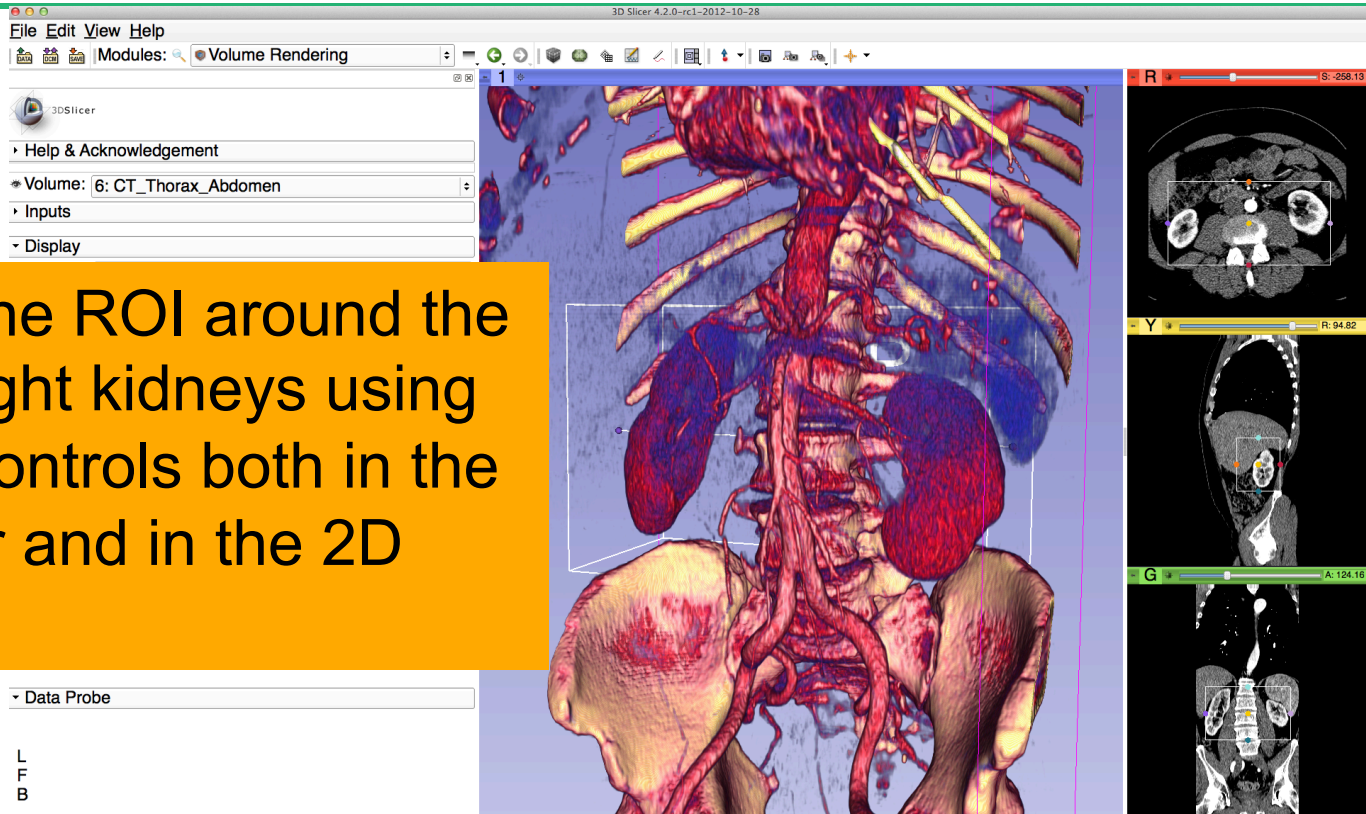
GPU Volume Rendering



Use the right-mouse button to zoom in.
Click on **Display ROI** to display a region of interest that we will use for cropping the dataset.



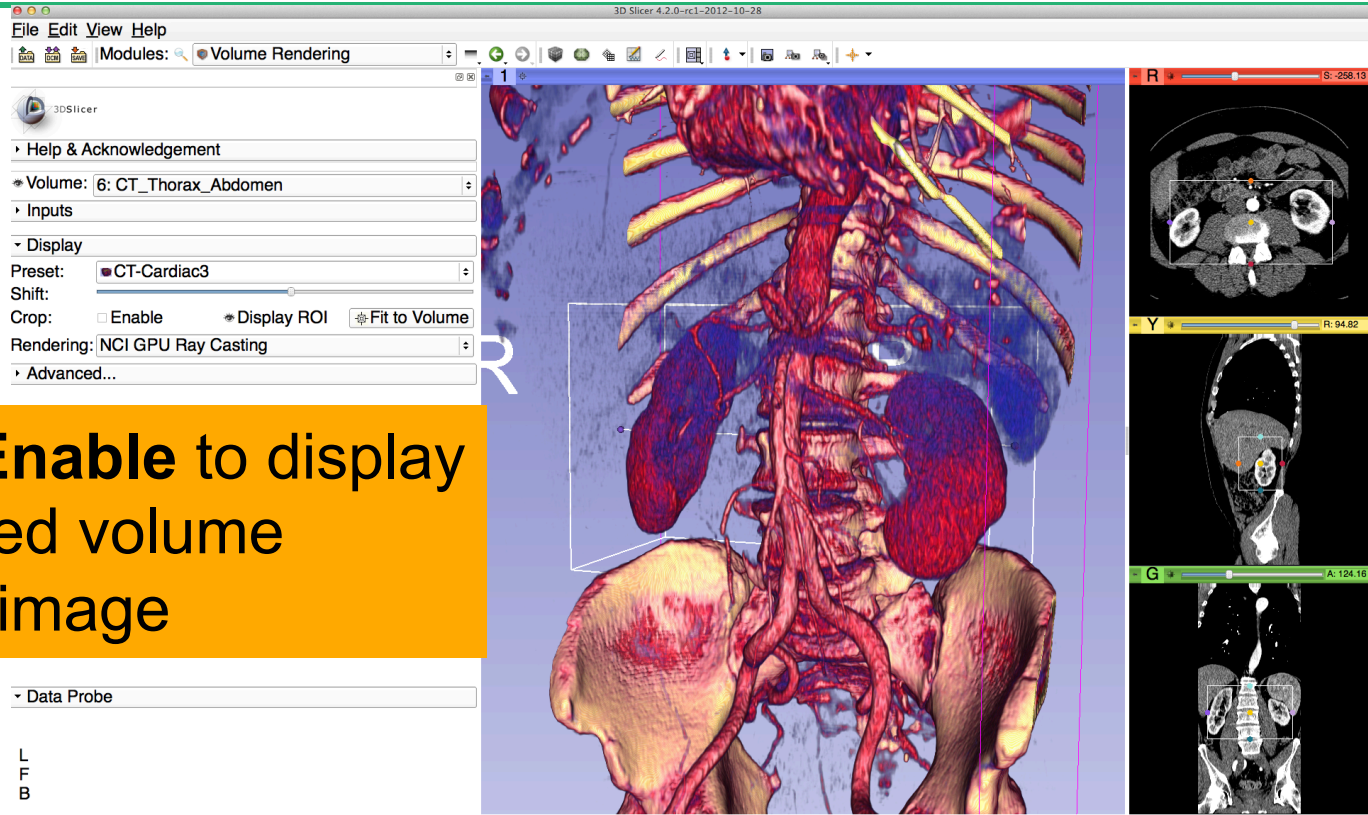
GPU Volume Rendering



Position the ROI around the left and right kidneys using the ROI controls both in the 3D viewer and in the 2D views



GPU Volume Rendering



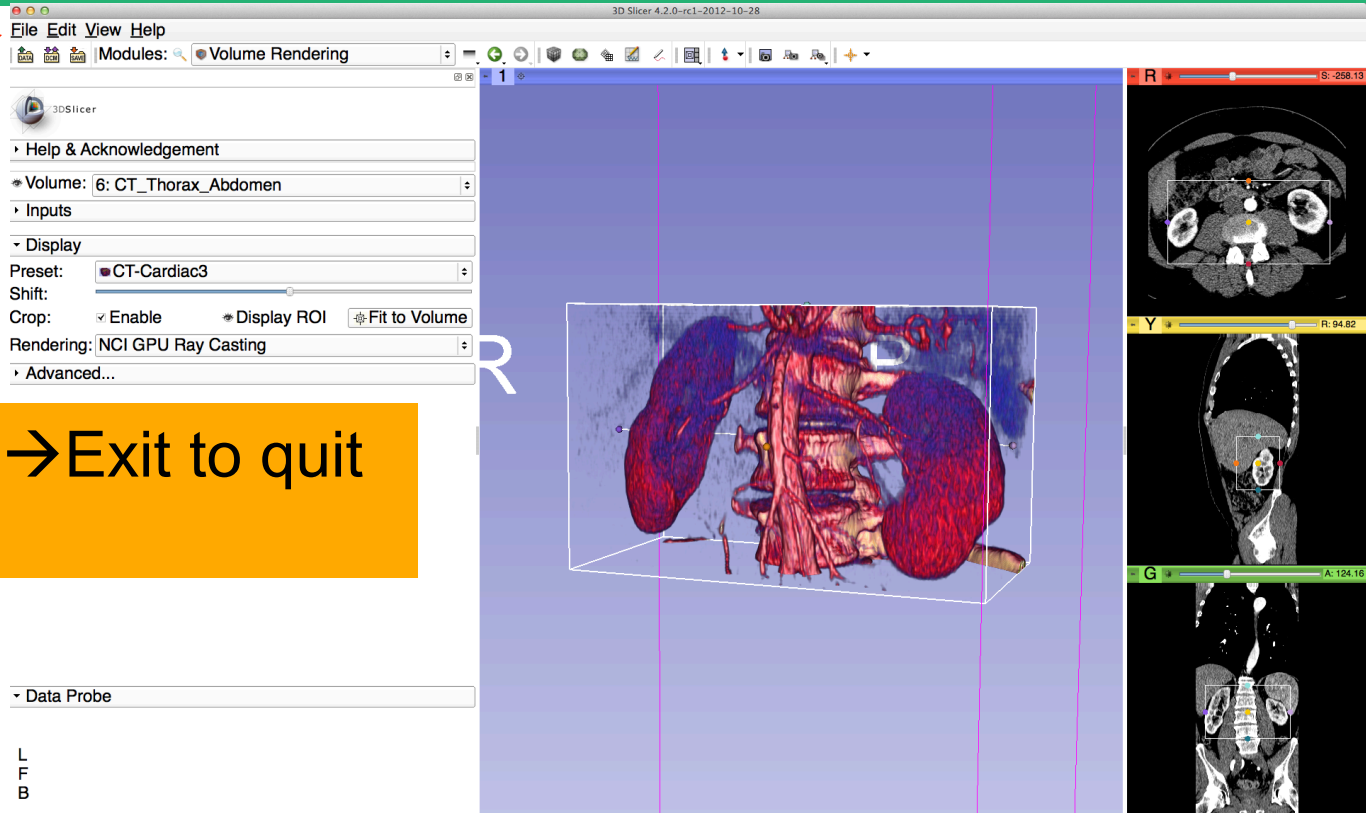
Click on **Enable** to display the cropped volume rendered image



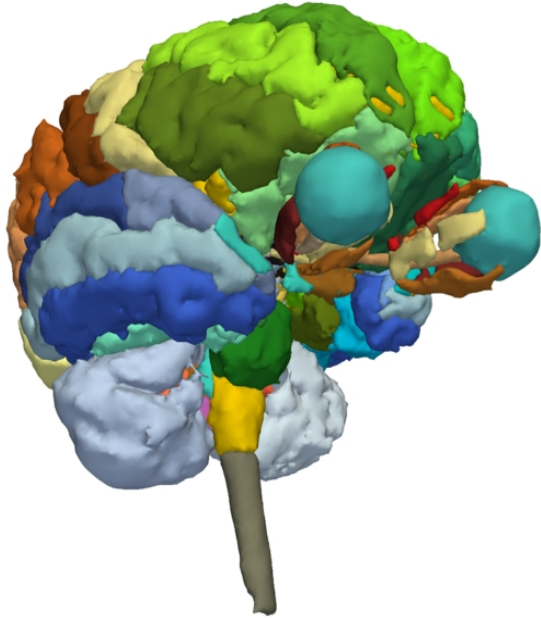
LFB



GPU Volume Rendering



Click on File→Exit to quit
Slicer

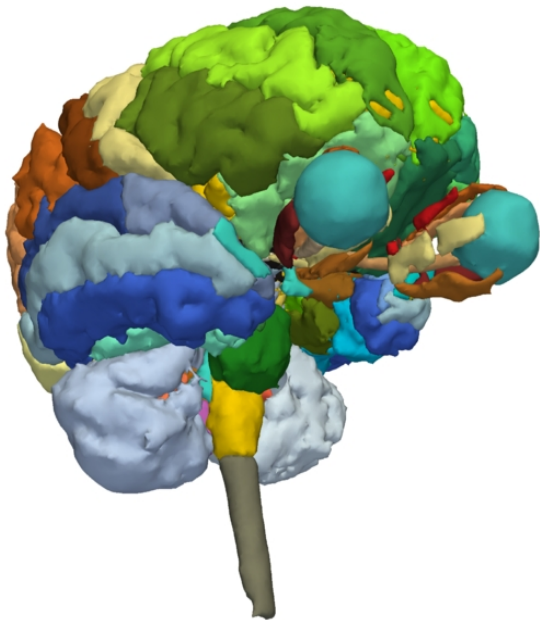


Part 2:

3D visualization of surface models of the brain



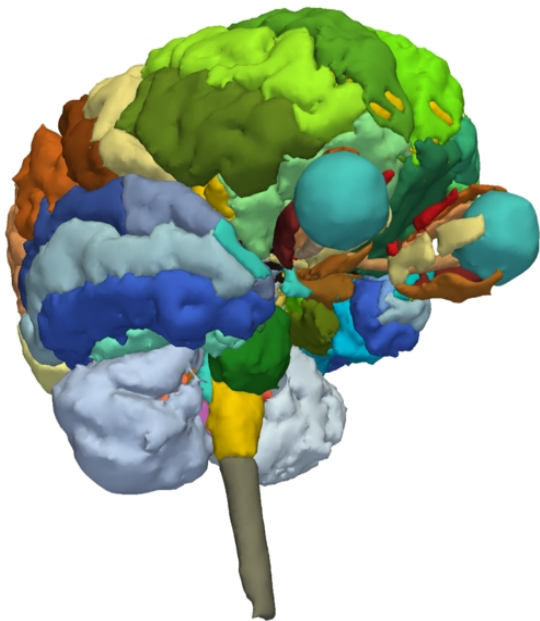
3D Slicer Scene



- A Slicer scene is a MRML file which contains a list of elements loaded into Slicer (volumes, models, fiducials...)
- The tutorial scene contains an MR scan of the brain and 3D surface models of anatomical structures.



3D models of the brain



- The tutorial data are part of the SPL-PNL Brain Atlas developed by Thalos et al

- **RSNA 2011 Presentation:**

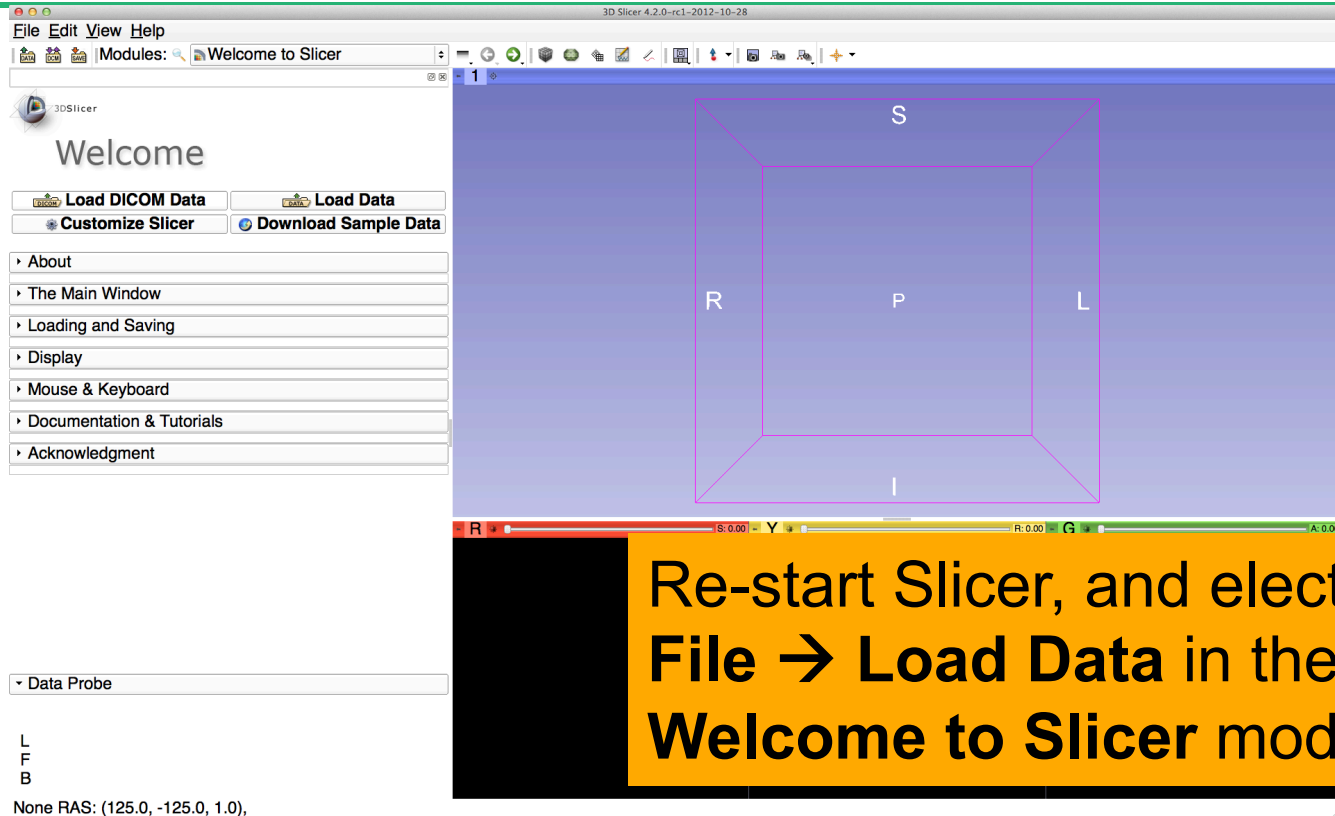
Publicly available RaxLex-linked Anatomy Atlases for Image Analysis Informatics and Education. Michael Halle, Samira Farough, Marianna Jakab, Ron Kikinis

Thurs. Dec.1st, 11:10-11:20 am

Room S402AB



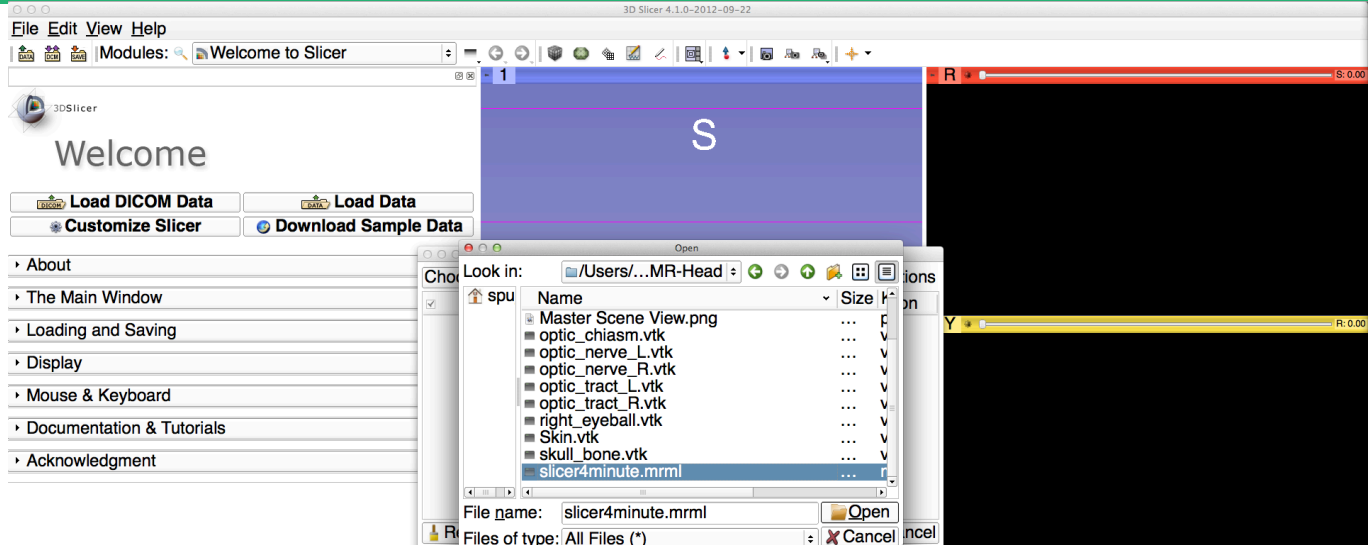
Loading a Scene



**Re-start Slicer, and elect
File → Load Data in the
Welcome to Slicer module**



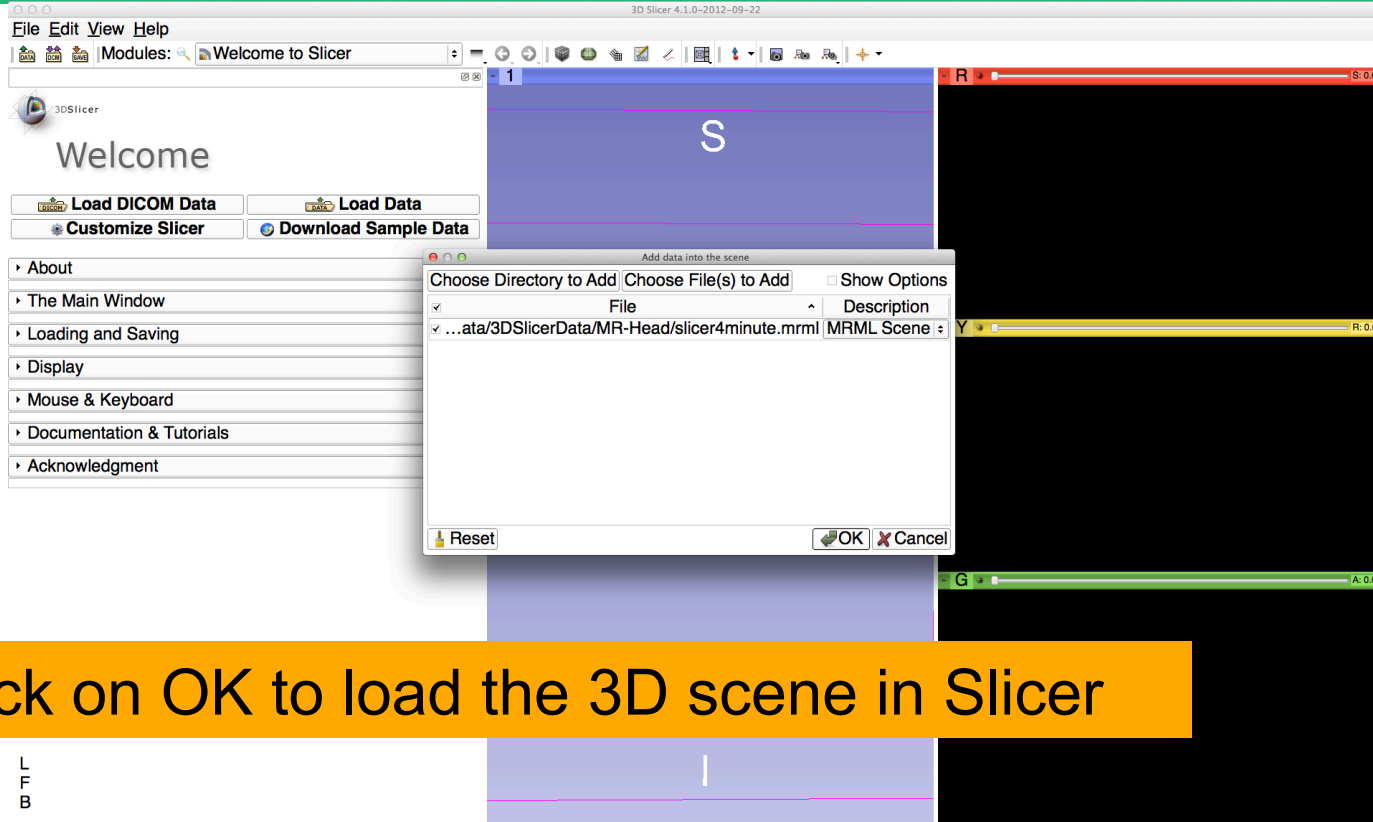
Loading a Scene



Browse to the directory **MR-Head**, located on the Desktop:
C:\Documents and Settings\Administrator\Desktop
\3DSlicerData
Select the file **slicer4minute.mrml**, and click on **Open**



Loading a Scene

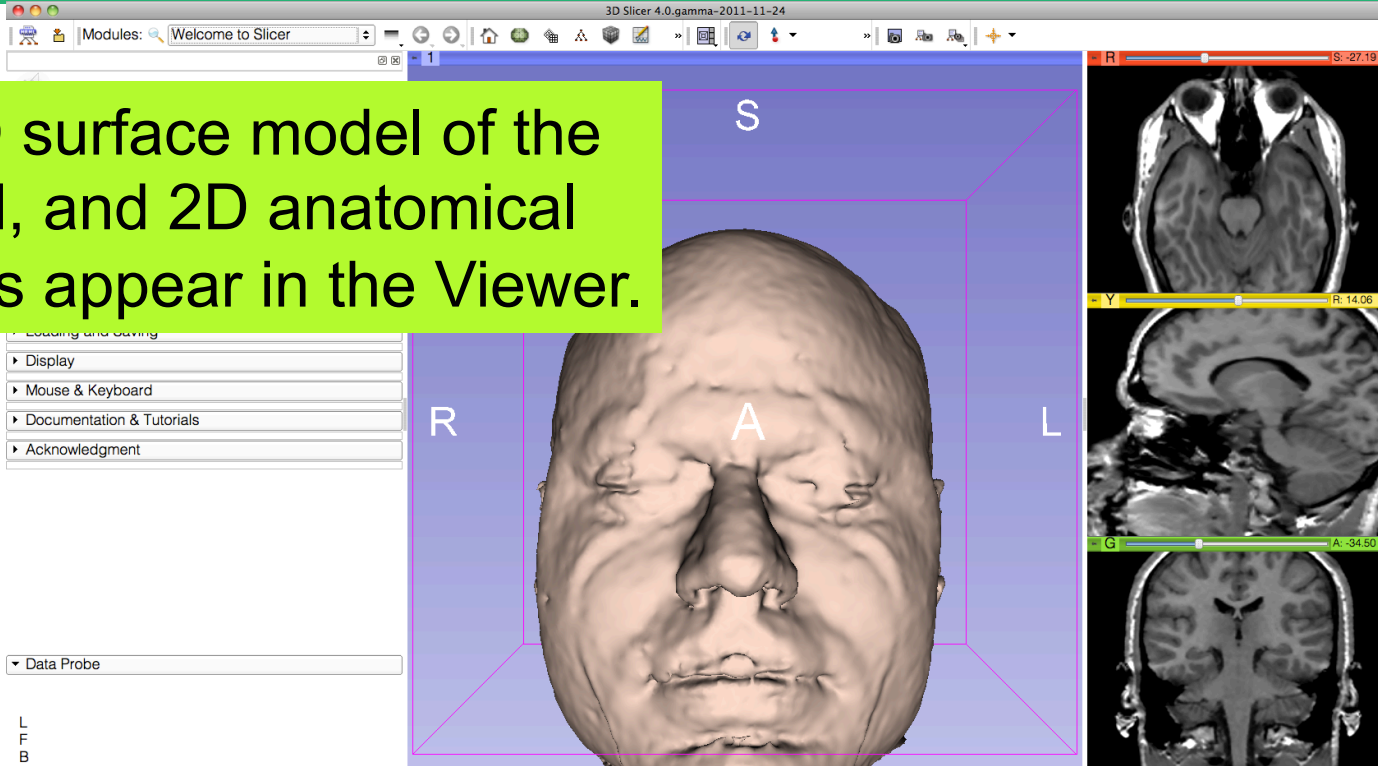


Click on OK to load the 3D scene in Slicer



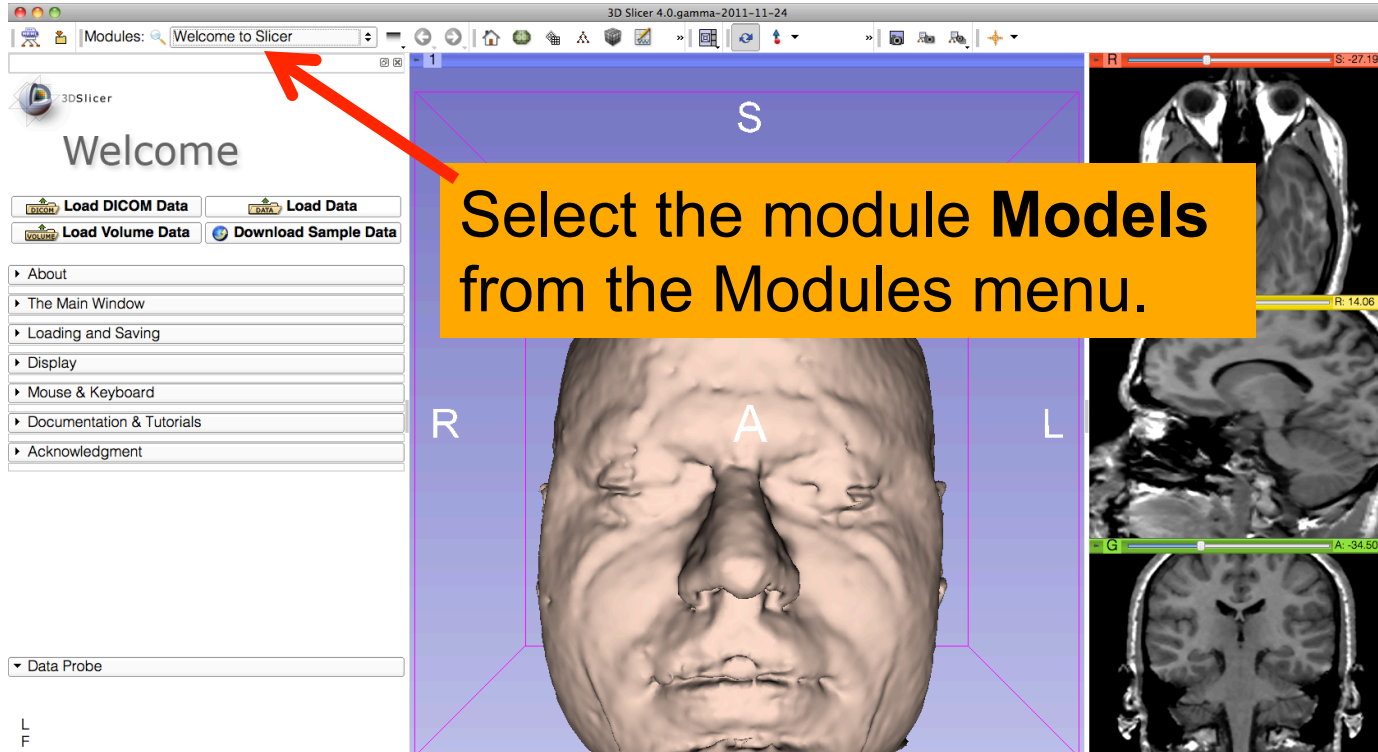
Loading the Slicer Scene

A 3D surface model of the head, and 2D anatomical slices appear in the Viewer.



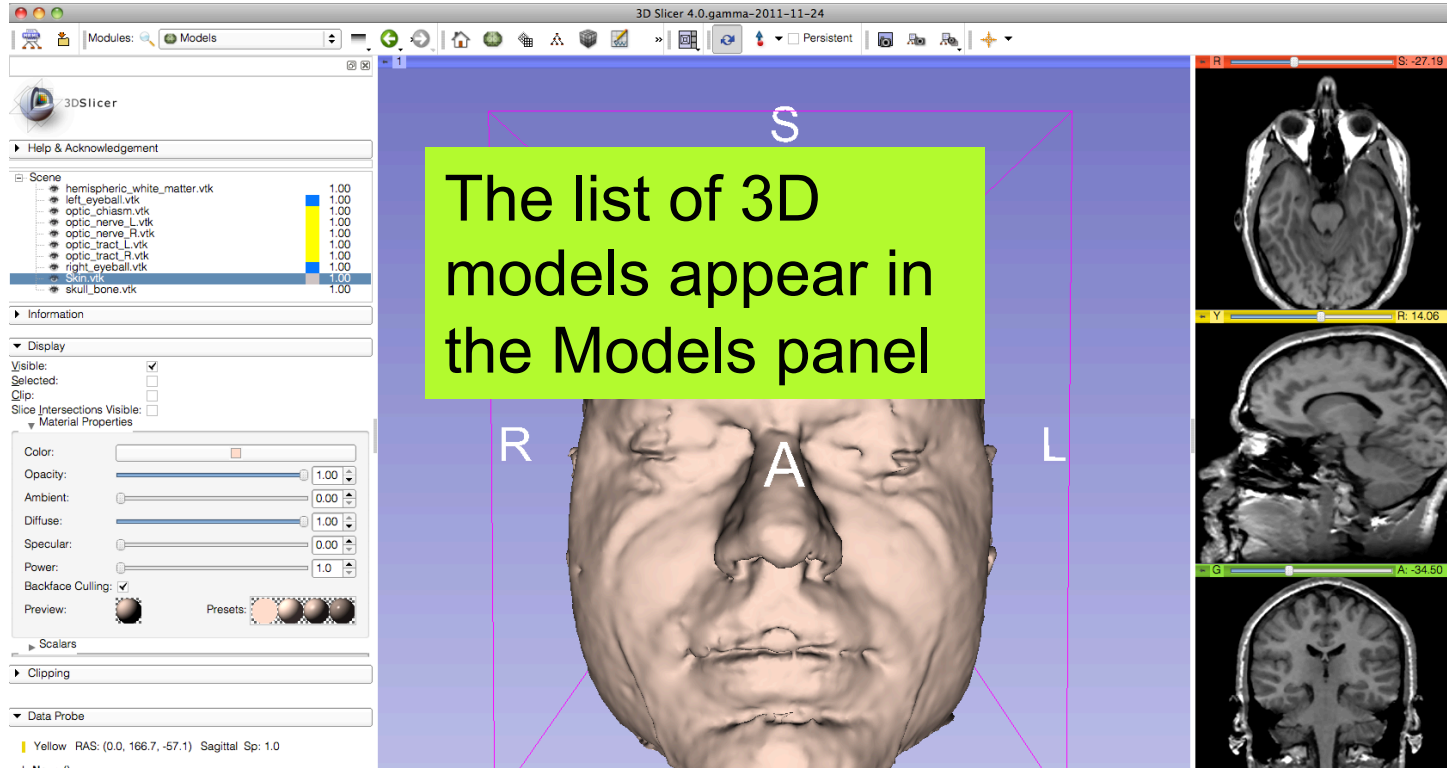


Loading the Slicer Scene





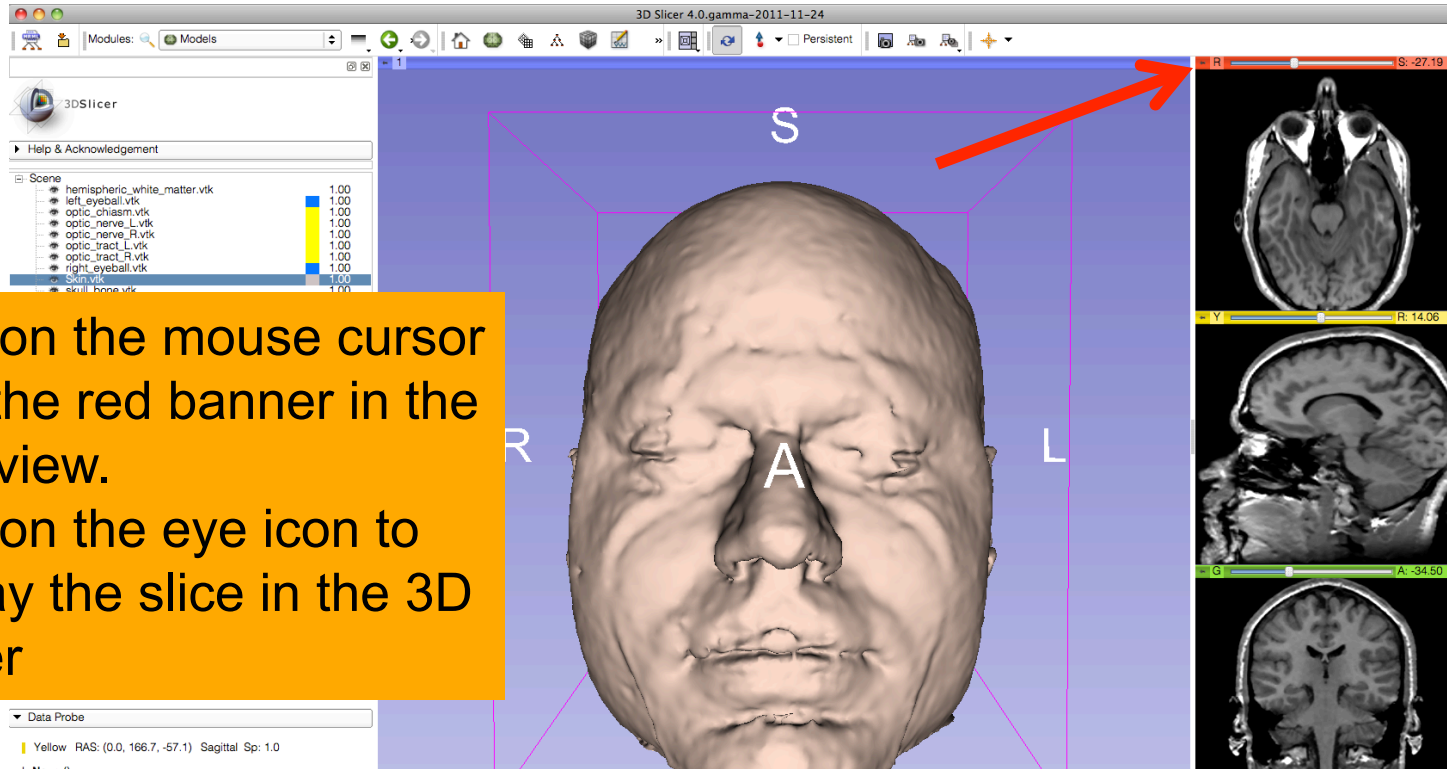
Models module





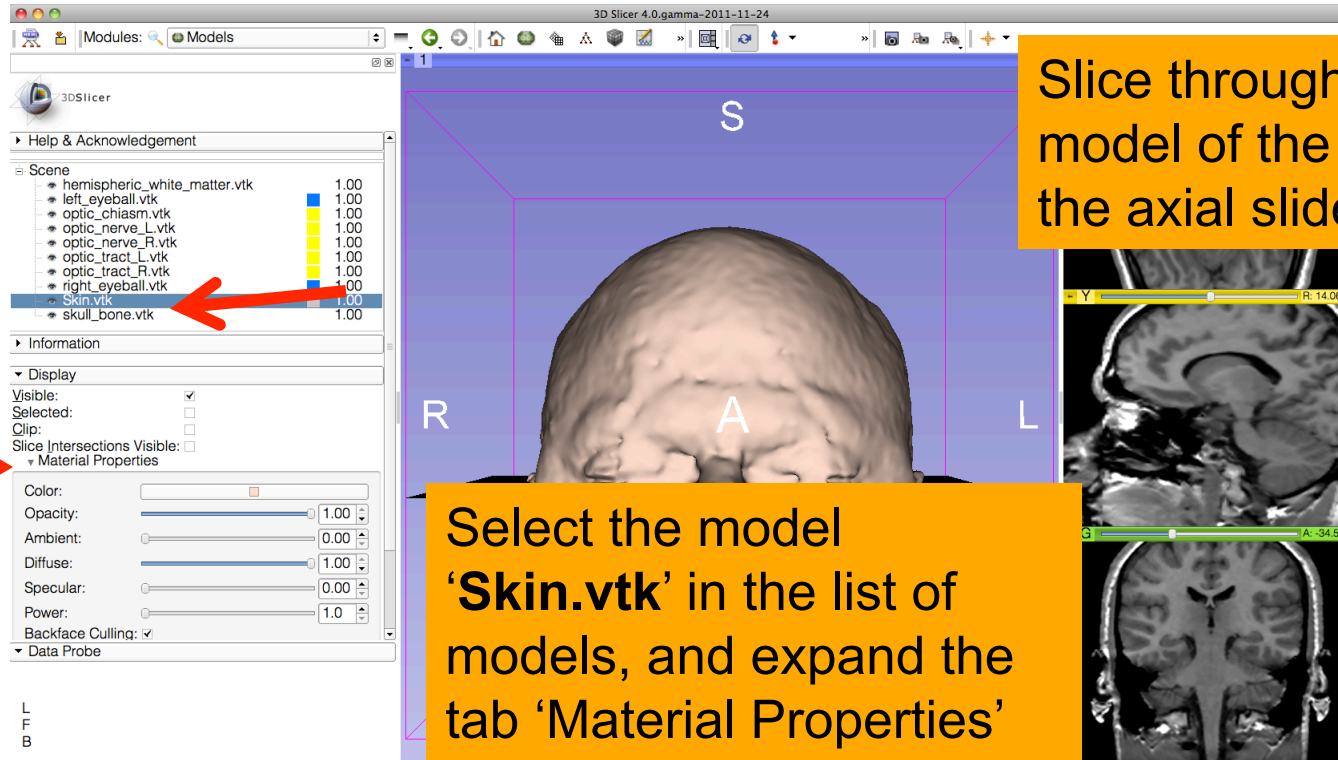
3D Visualization

Position the mouse cursor over the red banner in the axial view.
Click on the eye icon to display the slice in the 3D viewer

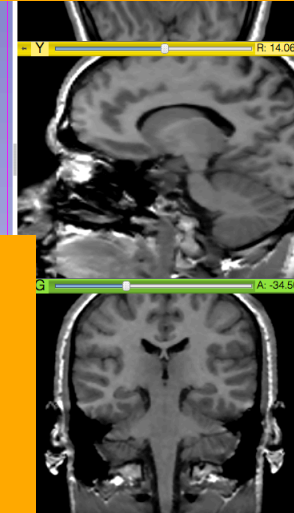




3D Visualization



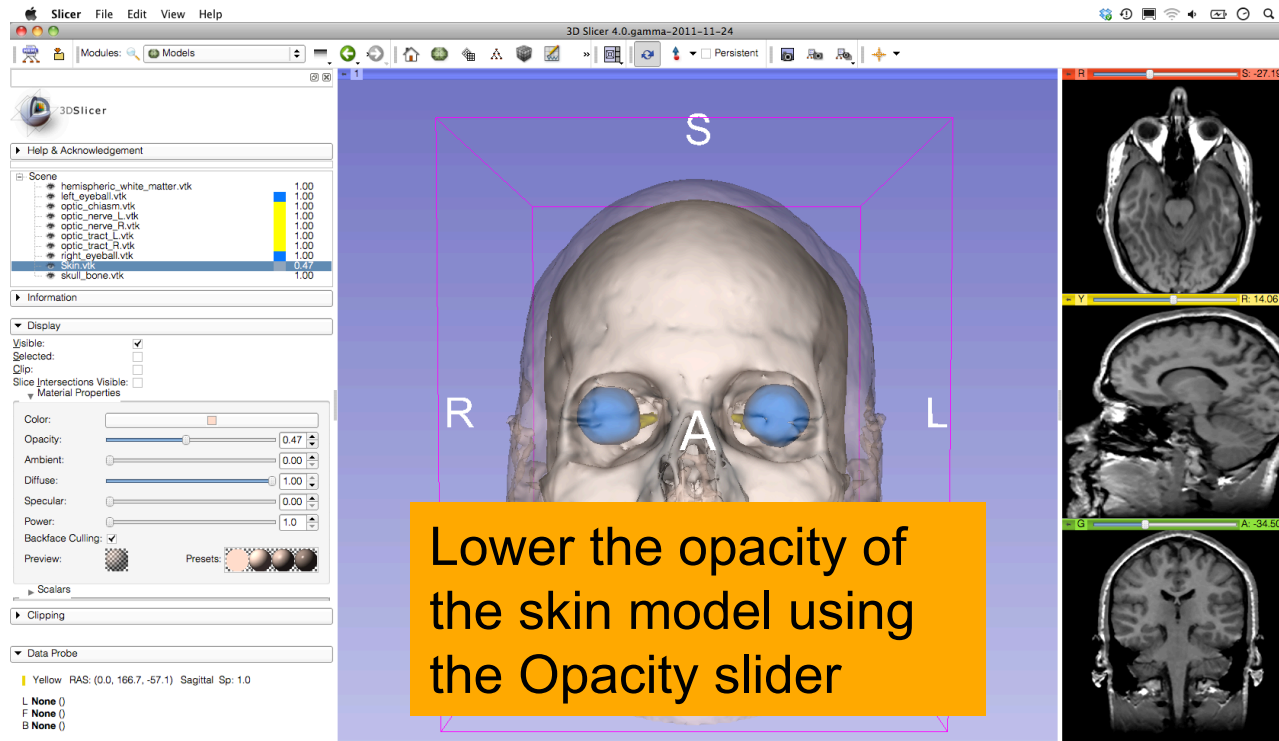
Slice through the 3D model of the head using the axial slider



Select the model 'Skin.vtk' in the list of models, and expand the tab 'Material Properties' under 'Display'

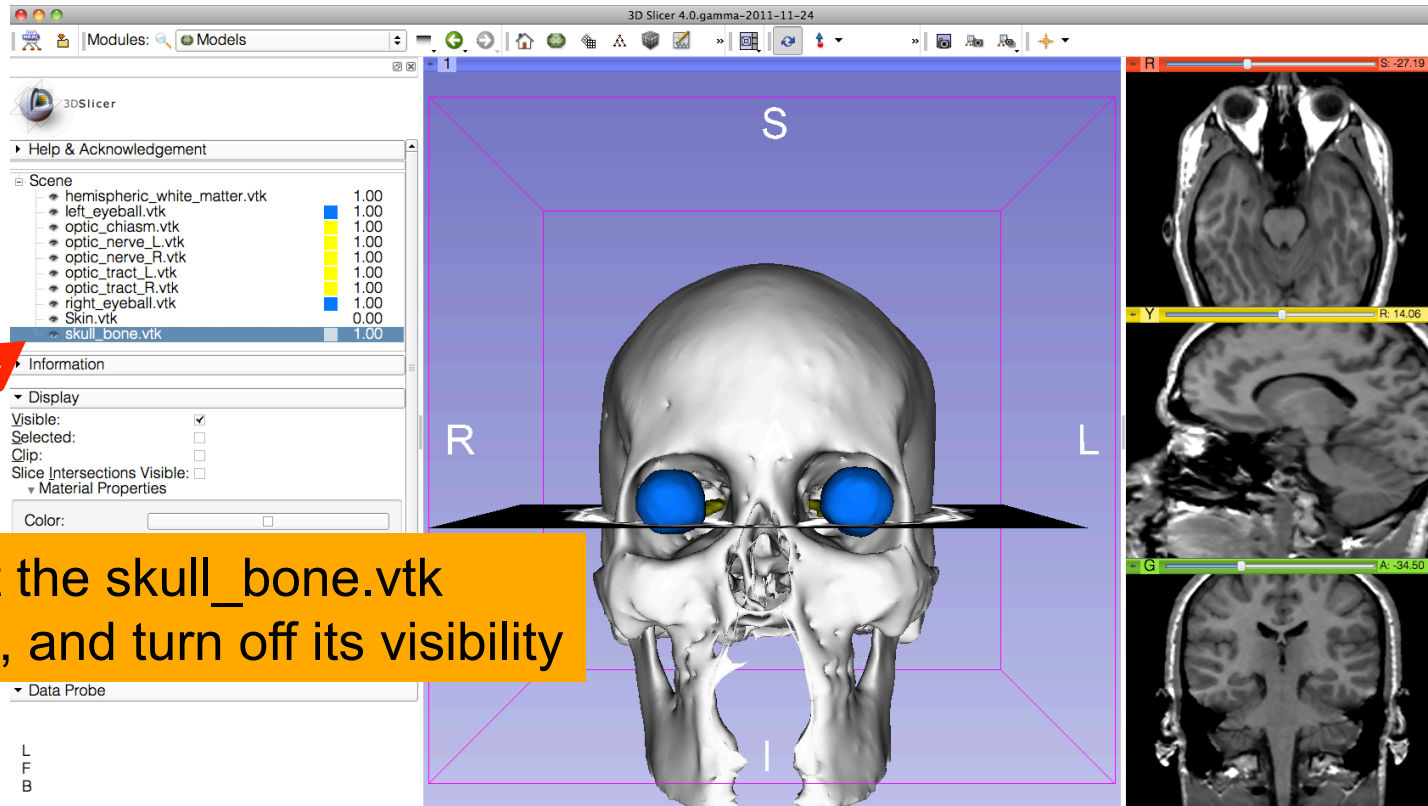


3D Visualization





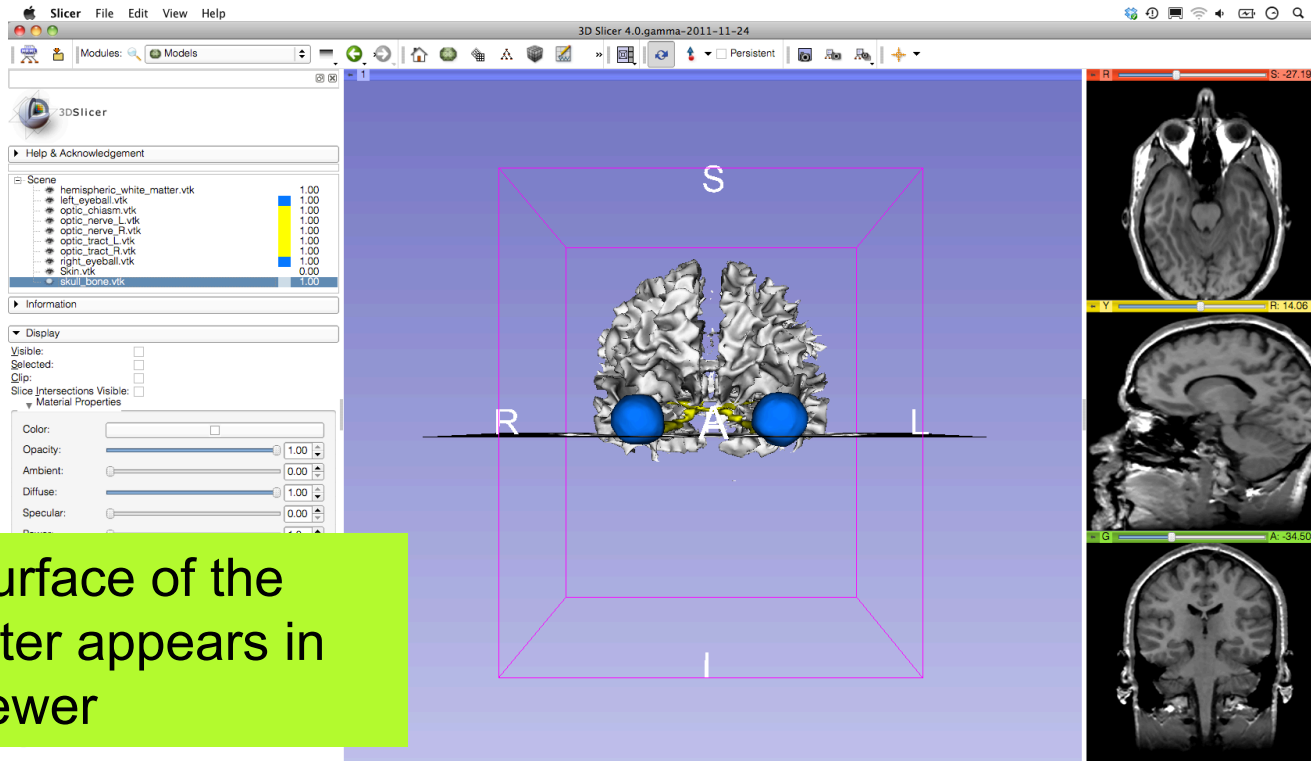
3D Visualization



Select the skull_bone.vtk model, and turn off its visibility



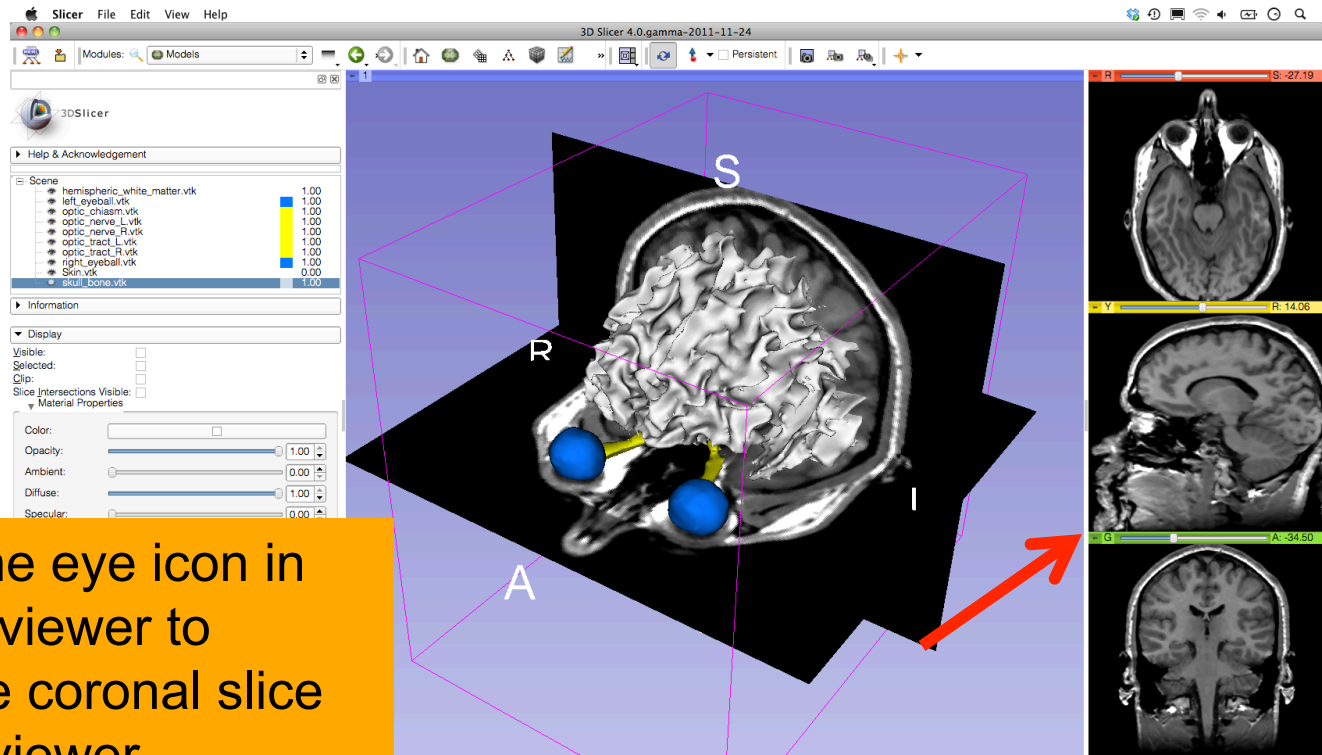
3D Visualization



The 3D surface of the white matter appears in the 3D viewer



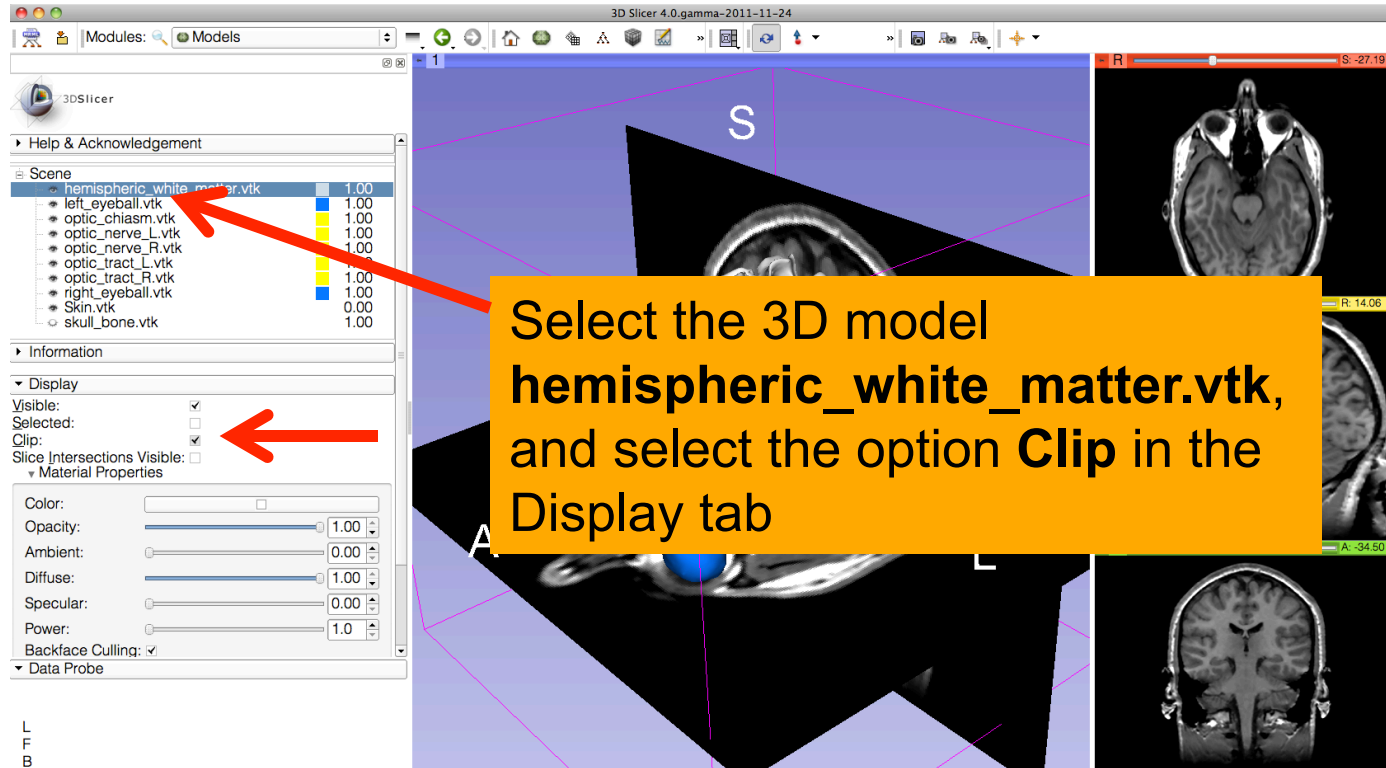
3D Visualization



Click on the eye icon in the green viewer to display the coronal slice in the 3D viewer

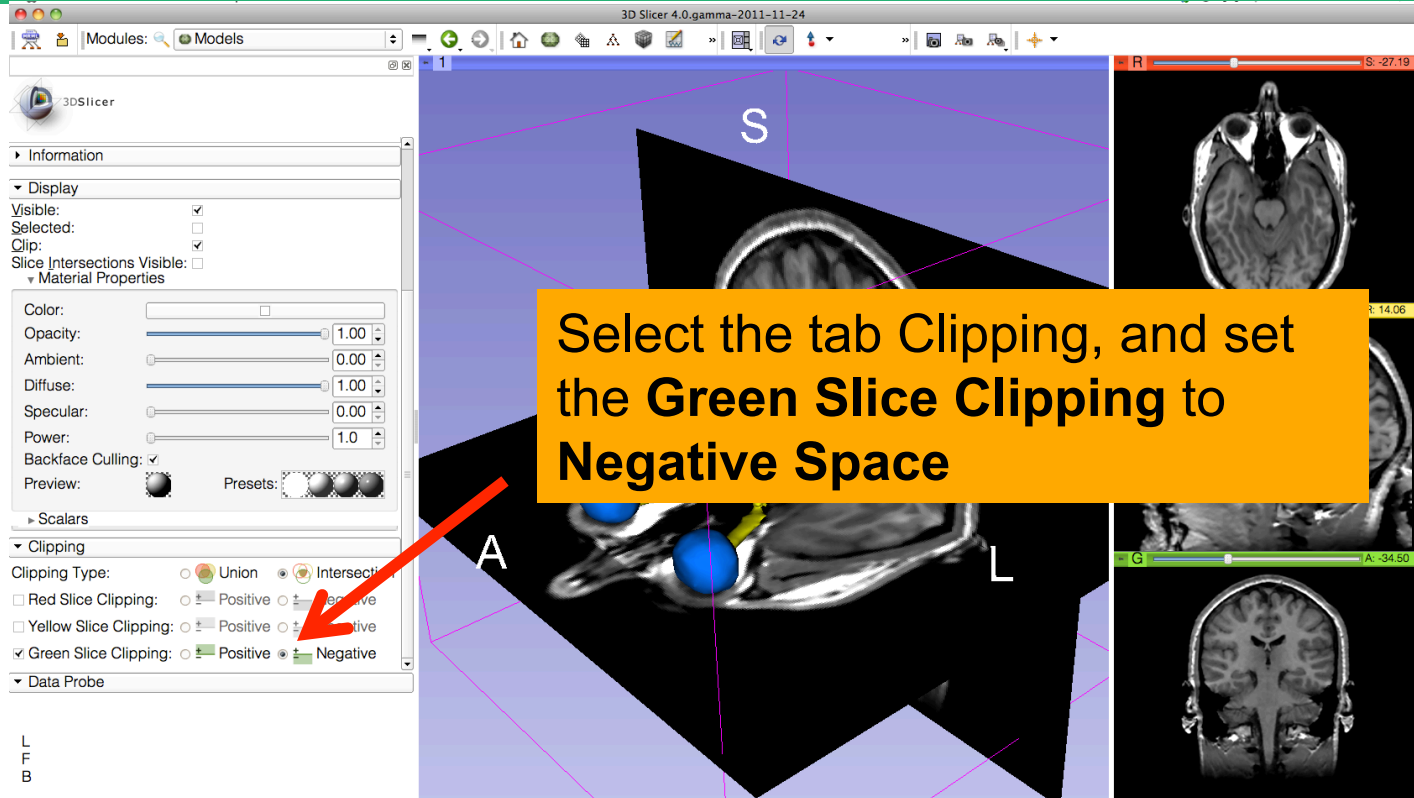


3D Visualization





3D Visualization

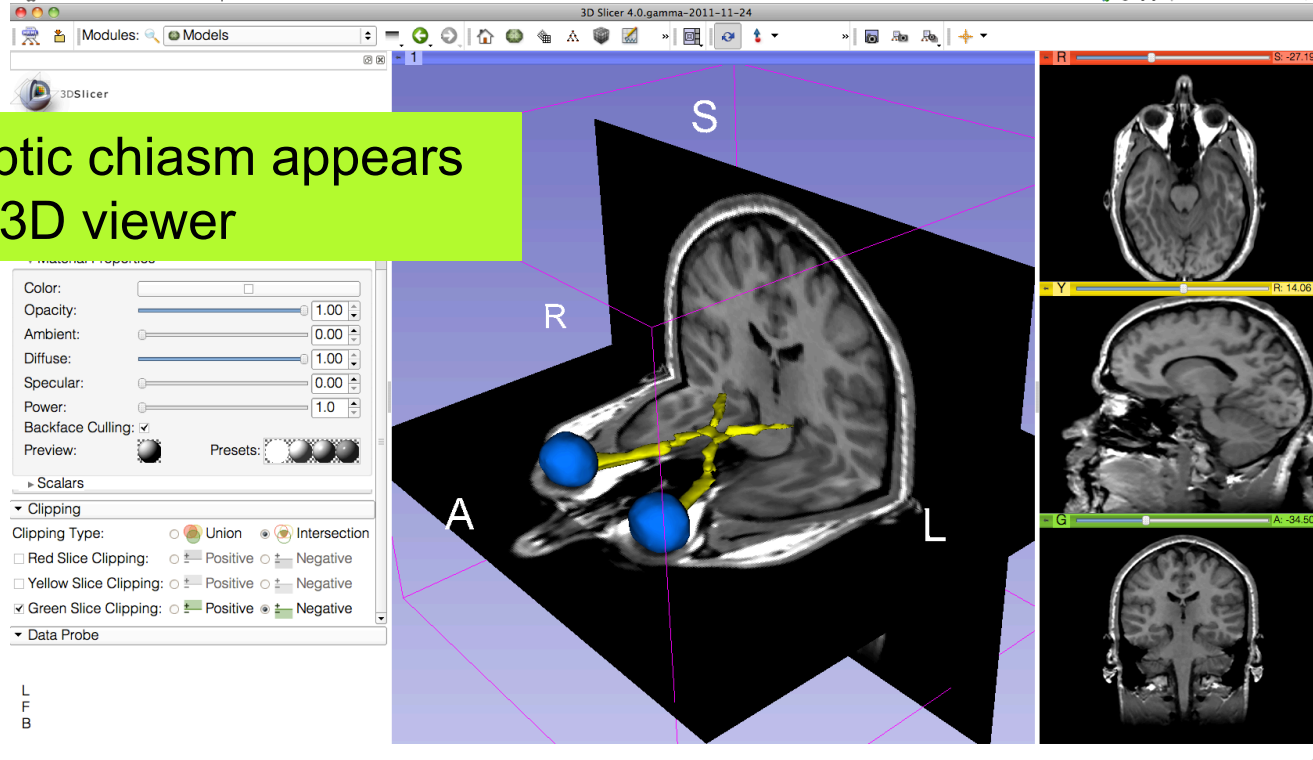


Select the tab Clipping, and set the **Green Slice Clipping** to **Negative Space**



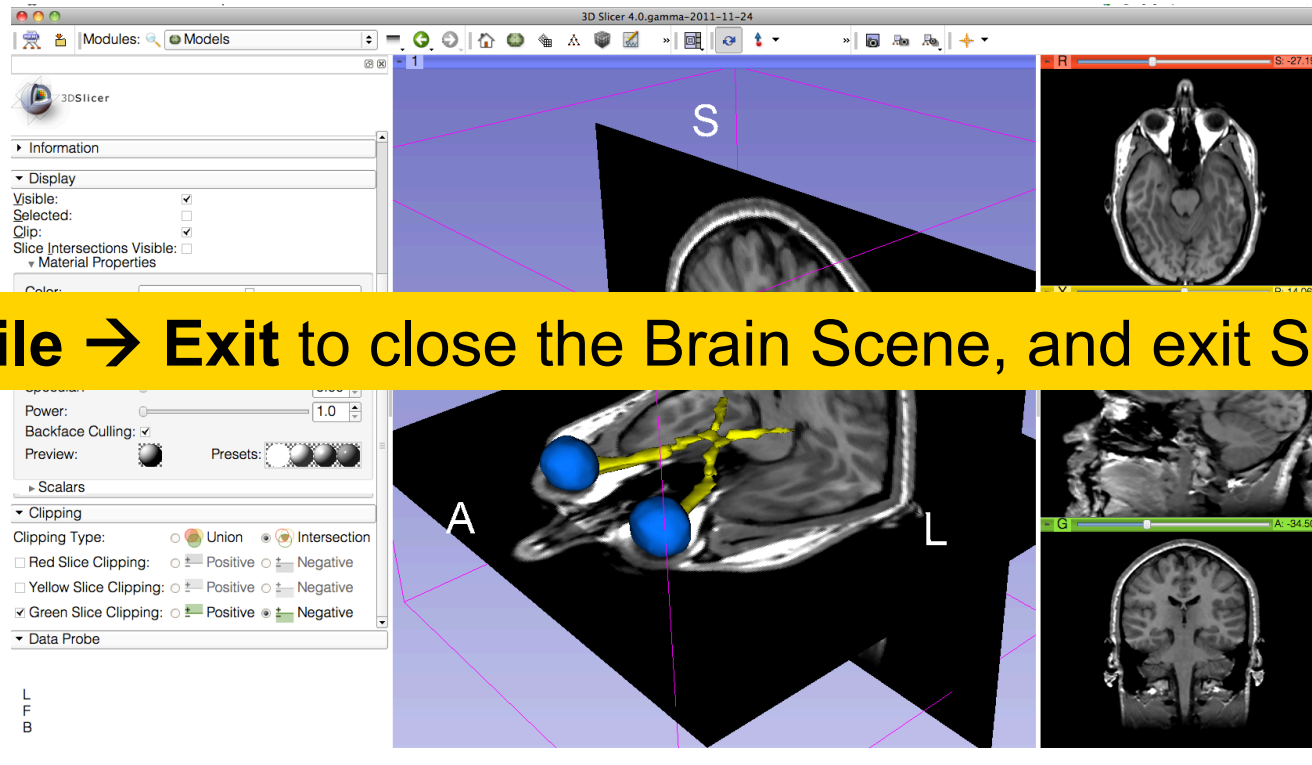
3D Visualization

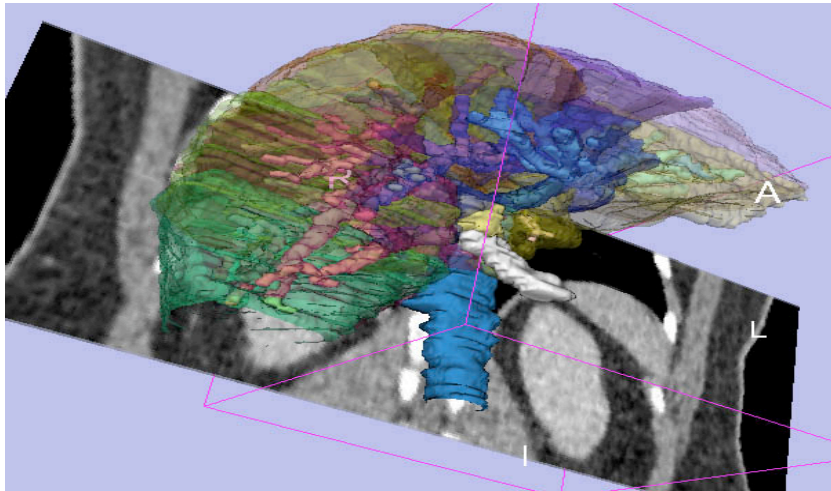
The optic chiasm appears
in the 3D viewer





3D Visualization

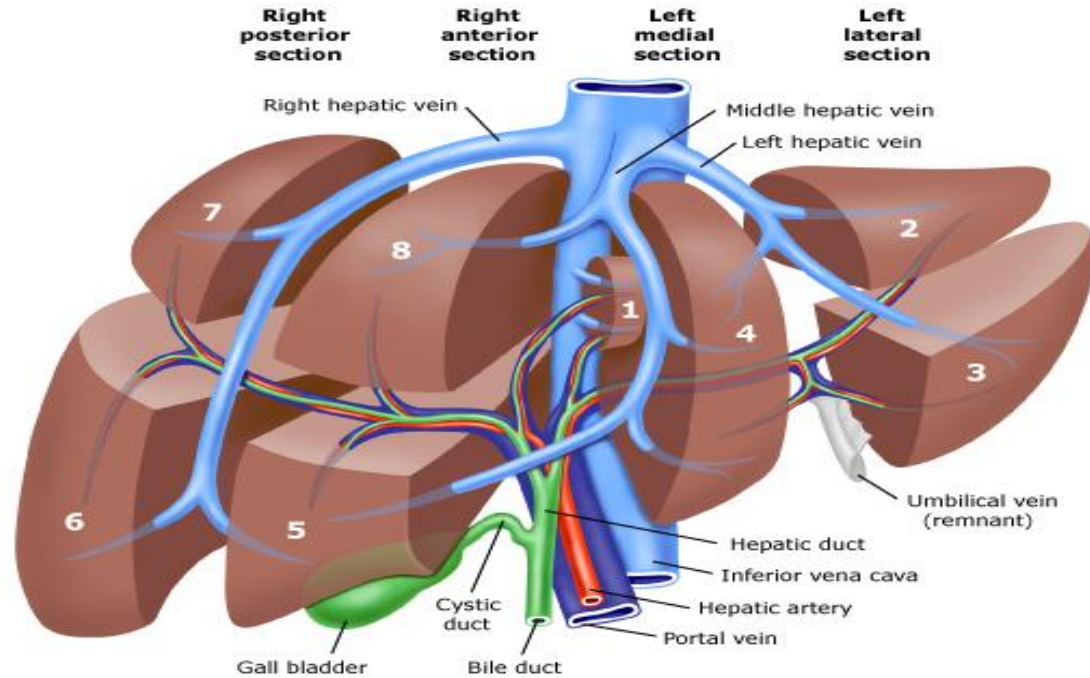




Part 4:

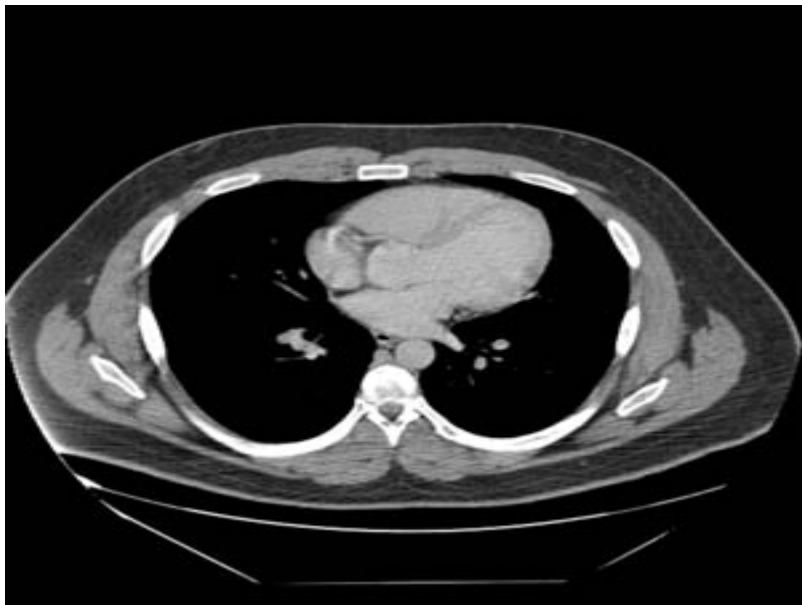
Interactive 3D Visualization
of the segments of the liver

Anatomy of the liver





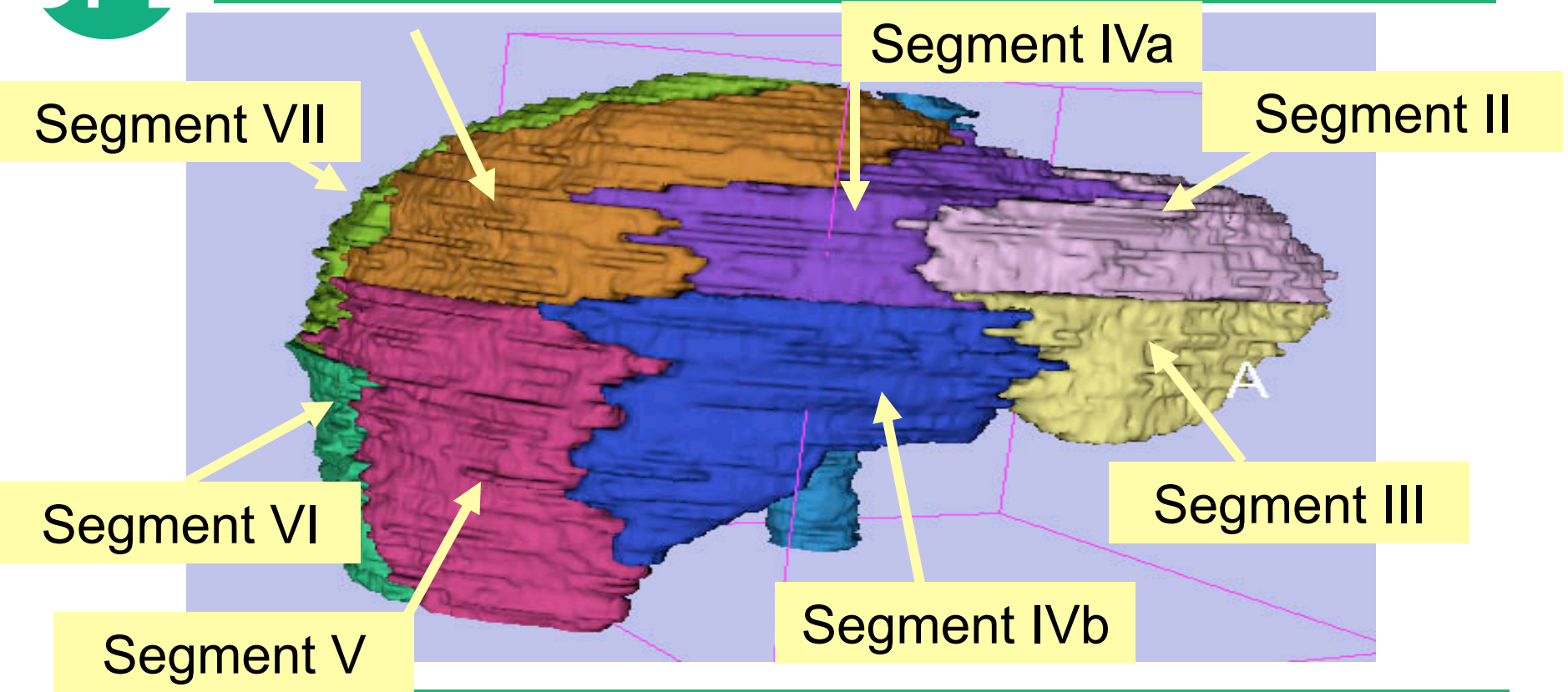
Liver dataset



The liver dataset is a contrast-enhanced CT abdominal scan of a healthy 36 year-old male.

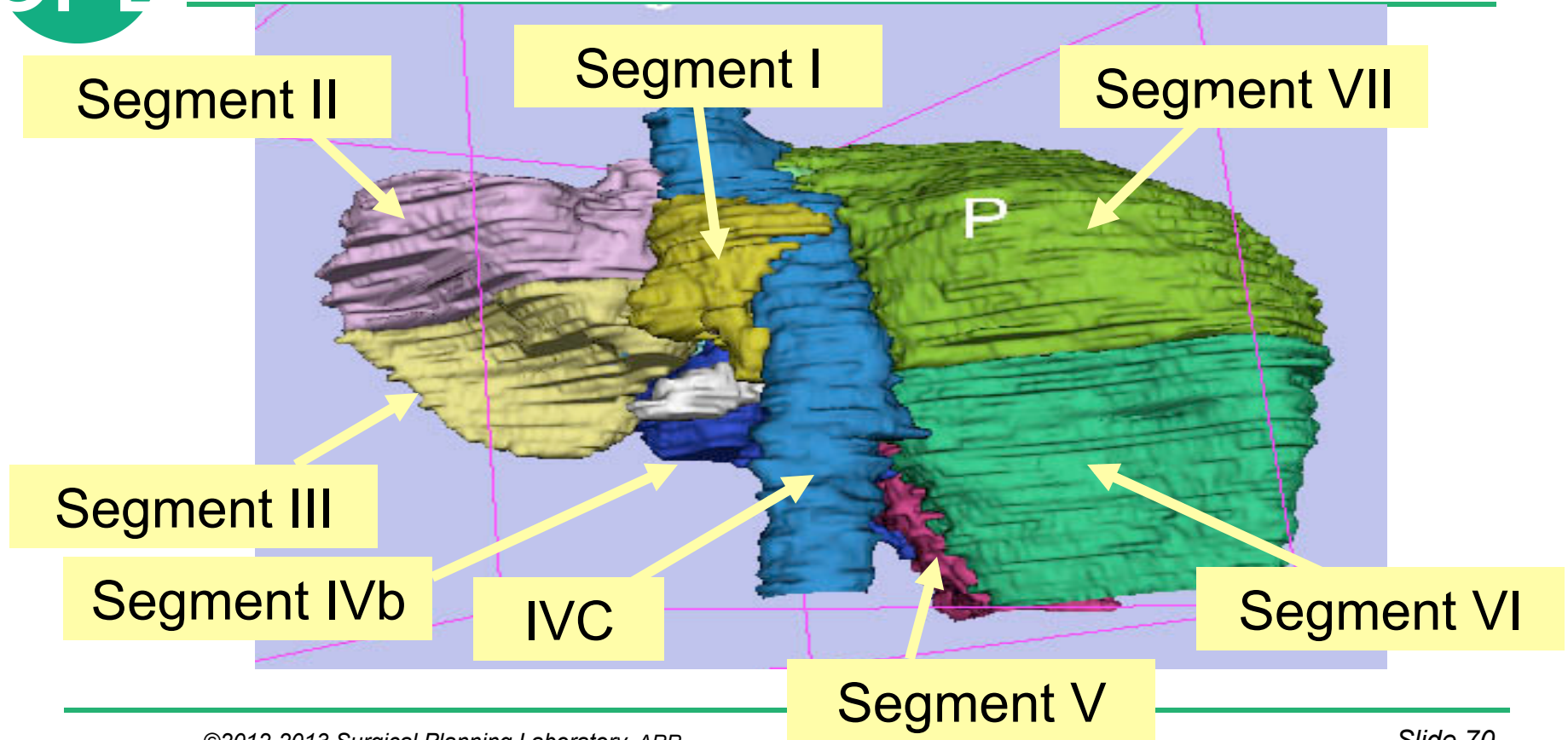


3D segments of the liver



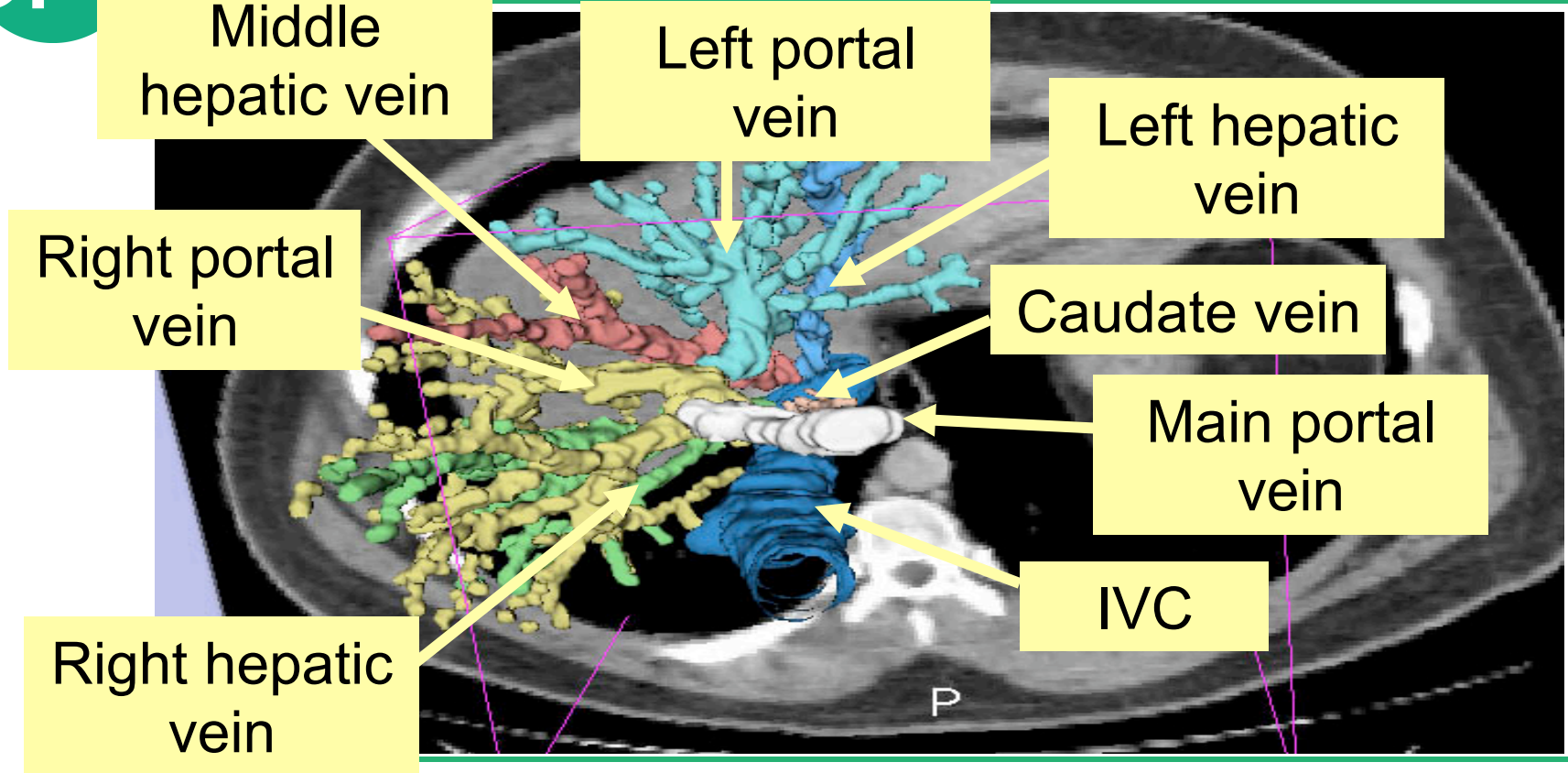


3D segments of the liver



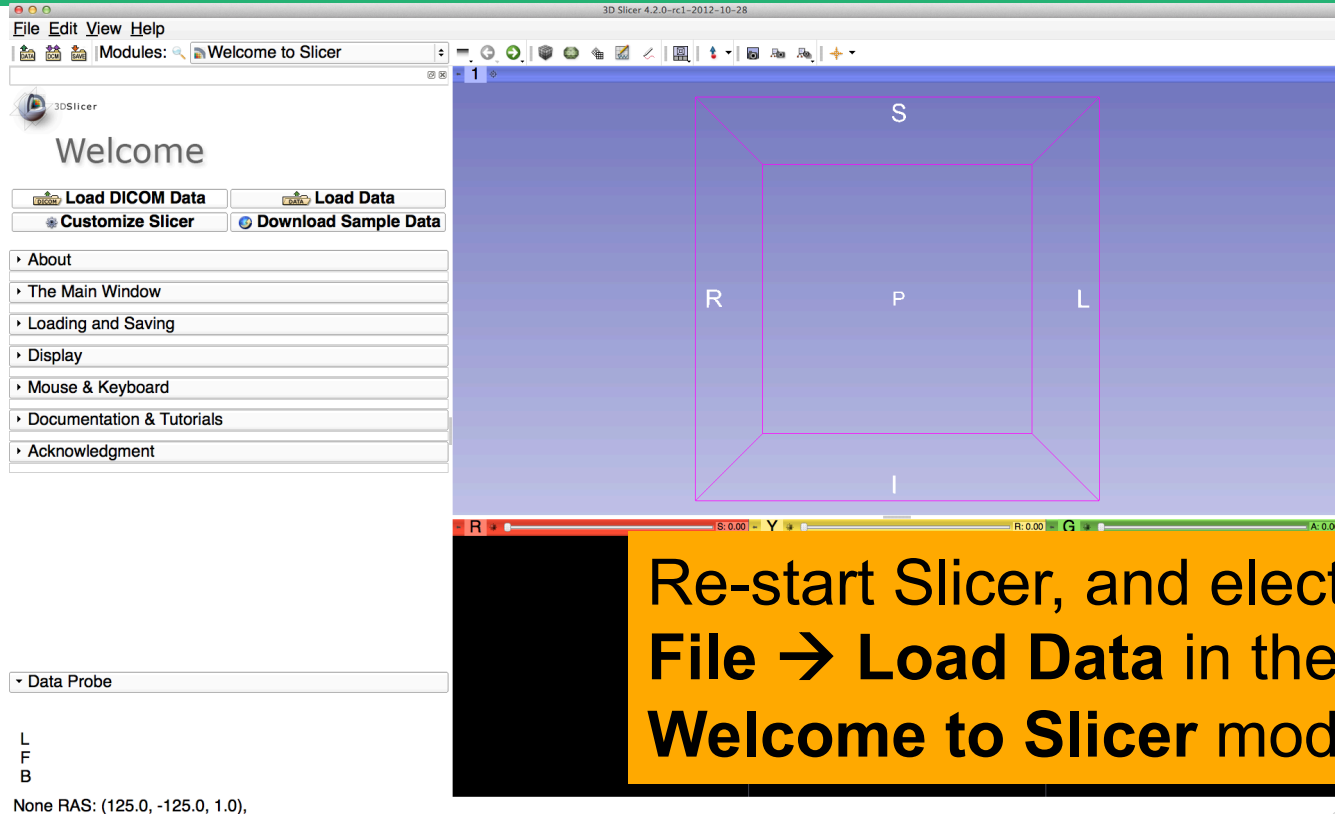


Liver vasculature





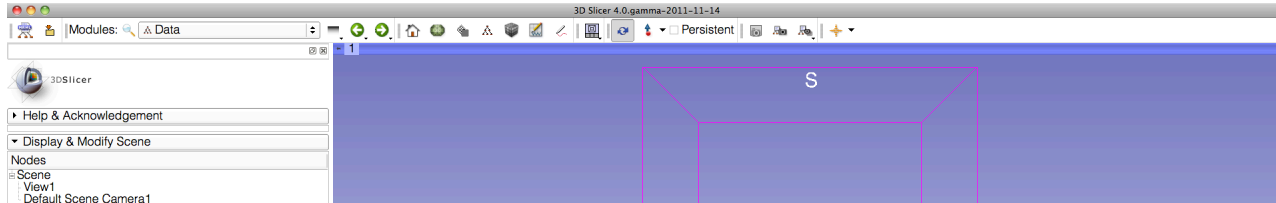
Loading the Liver Data Scene



Re-start Slicer, and elect
File → Load Data in the
Welcome to Slicer module




Loading the Liver Scene



Load the file **Scene-Liver.mrml** located in:

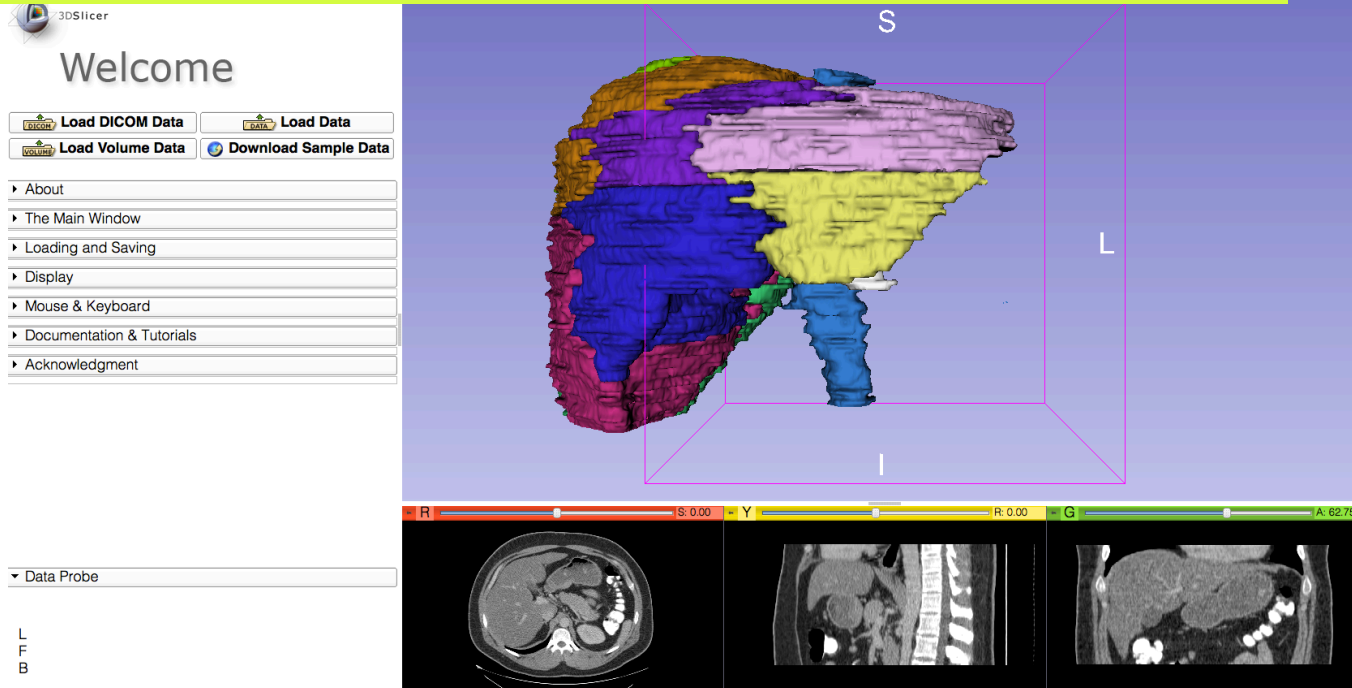
C:\Documents and Settings\Administrator\Desktop\3DSlicerData
\LiverData





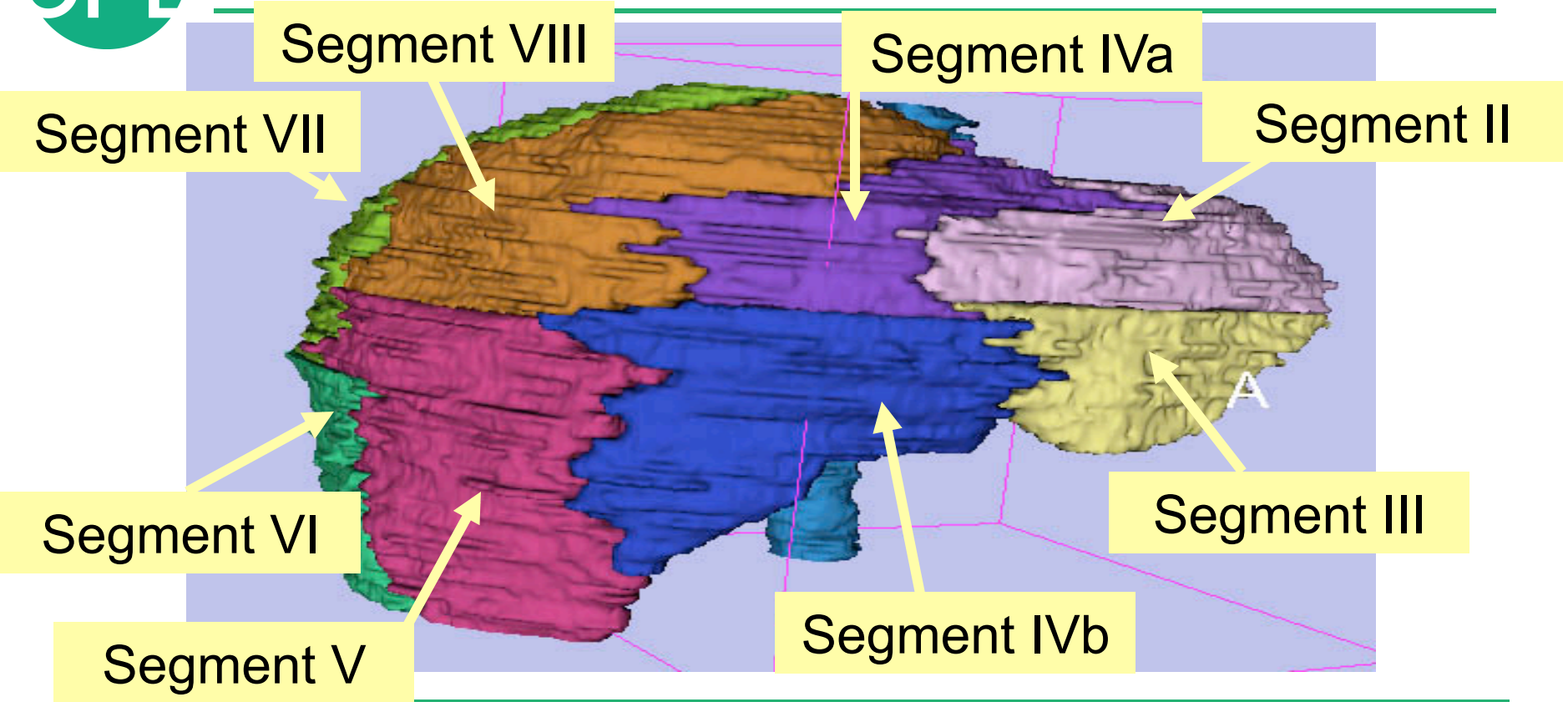
Liver Segments Scene

The elements of the scene appear in the Viewer



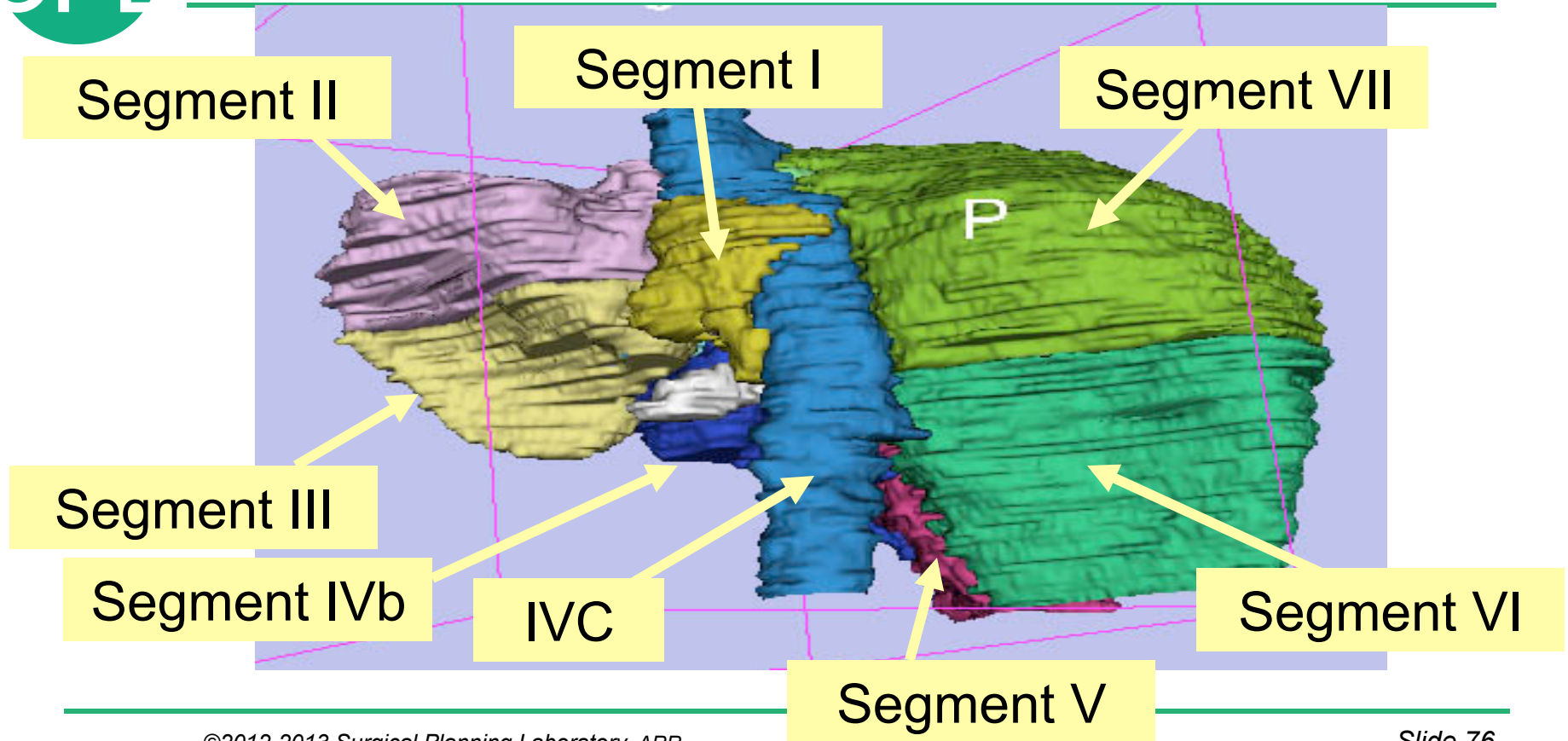


3D models of the liver



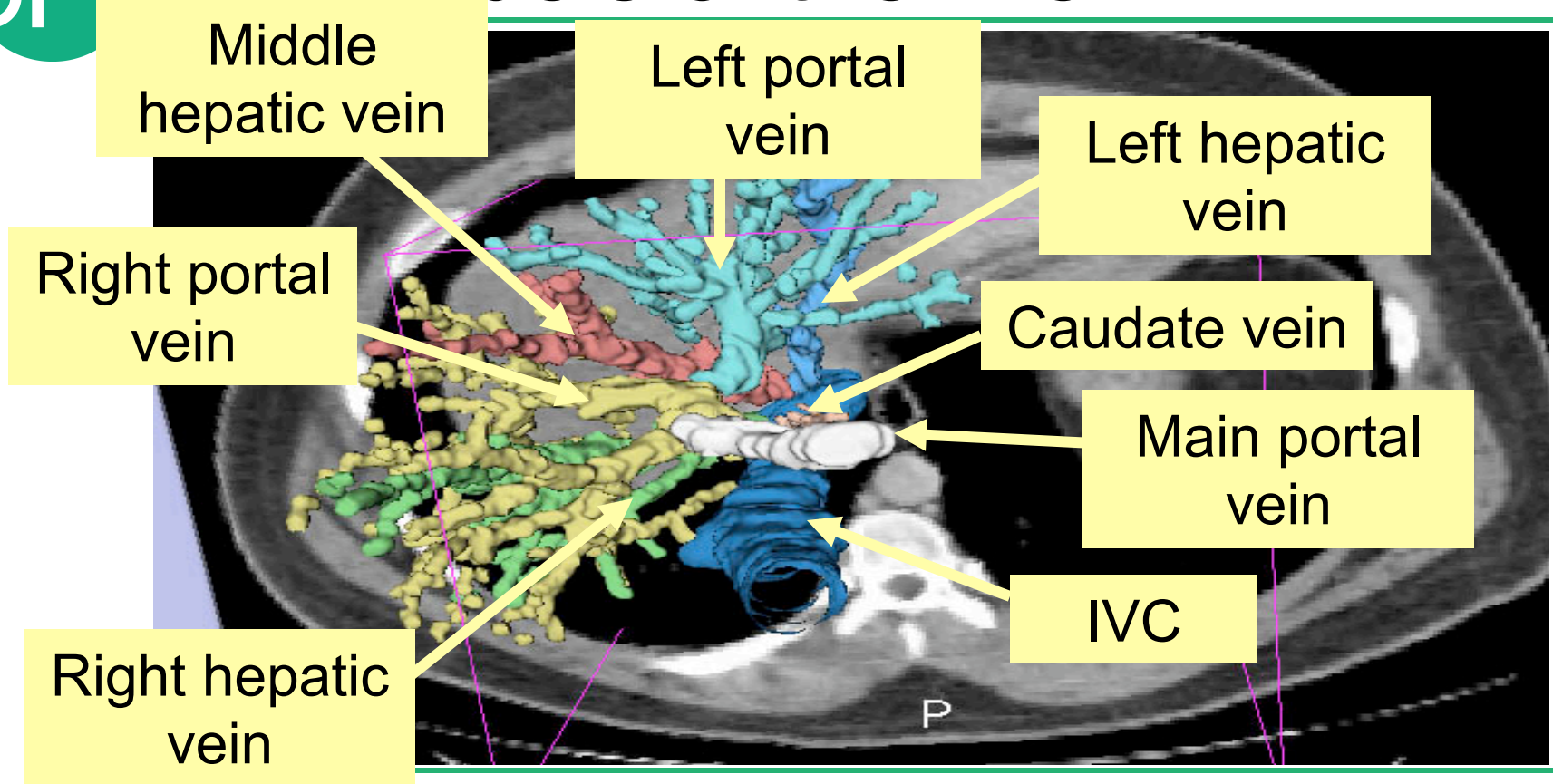


3D models of the liver



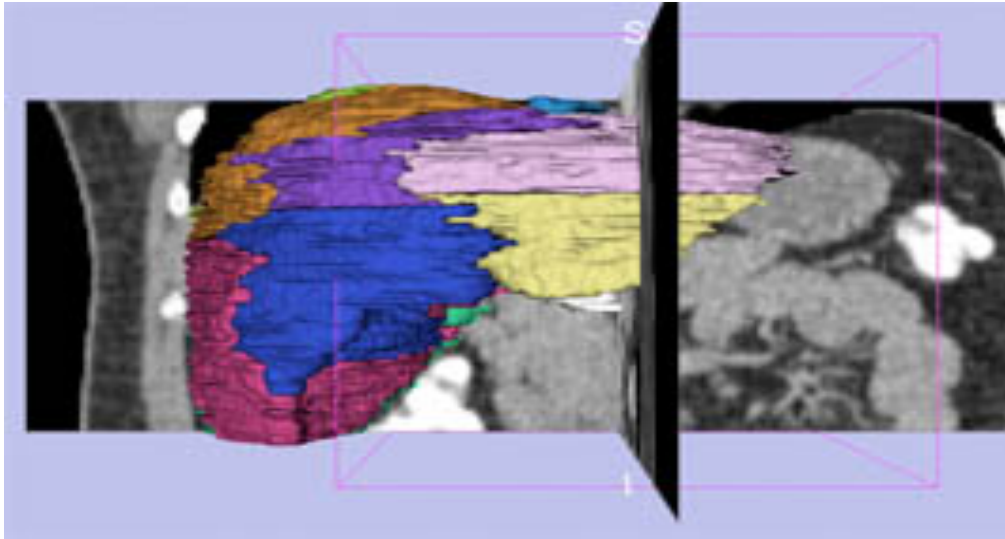


3D models of the liver





3D Exploration of Liver Segments

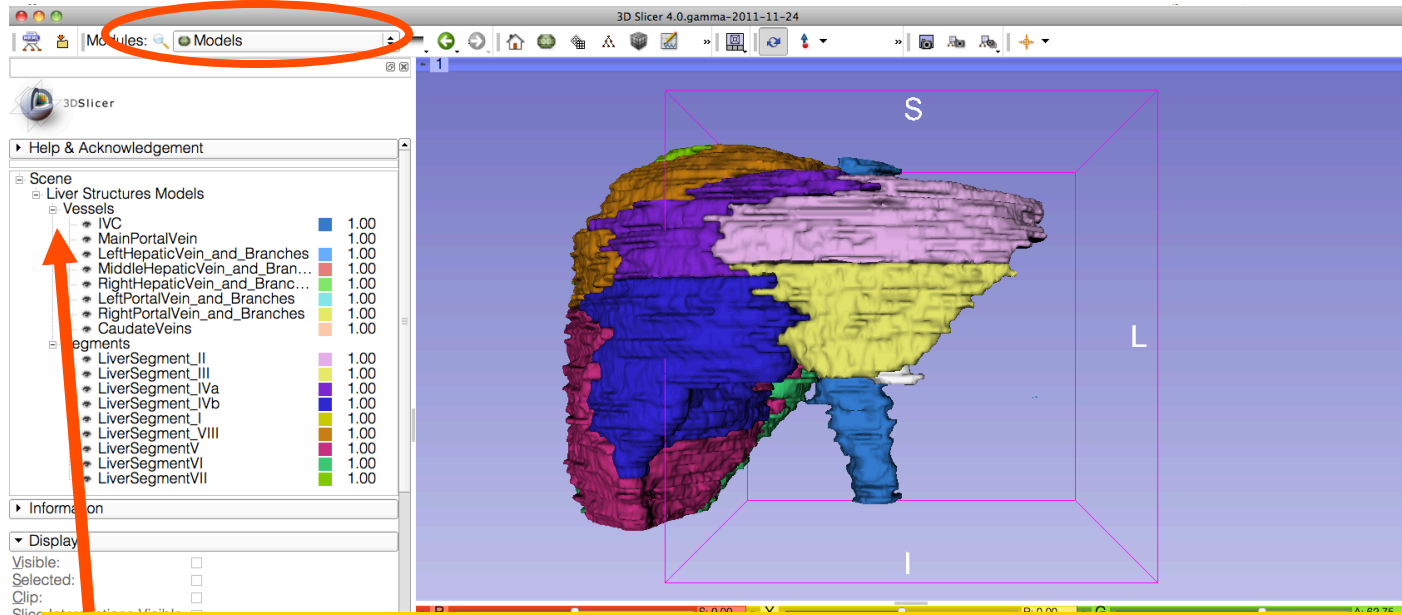


Example:

What organ abuts the left-most margin of segment II in this patient ?



3D Exploration of Liver Segments

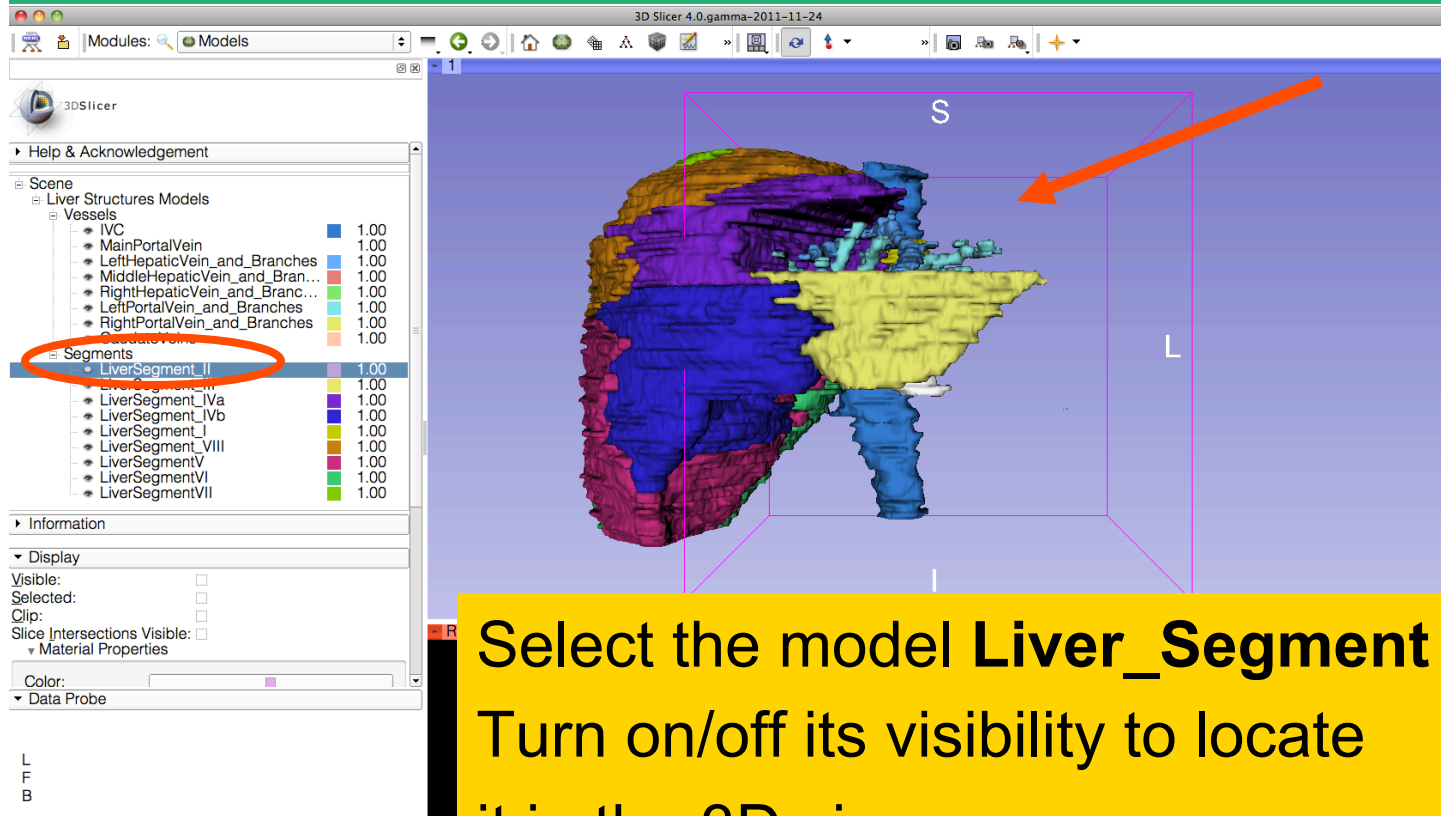


Select the module Models

Click on the Liver Structures Models Hierarchy



3D Exploration of Liver Segments

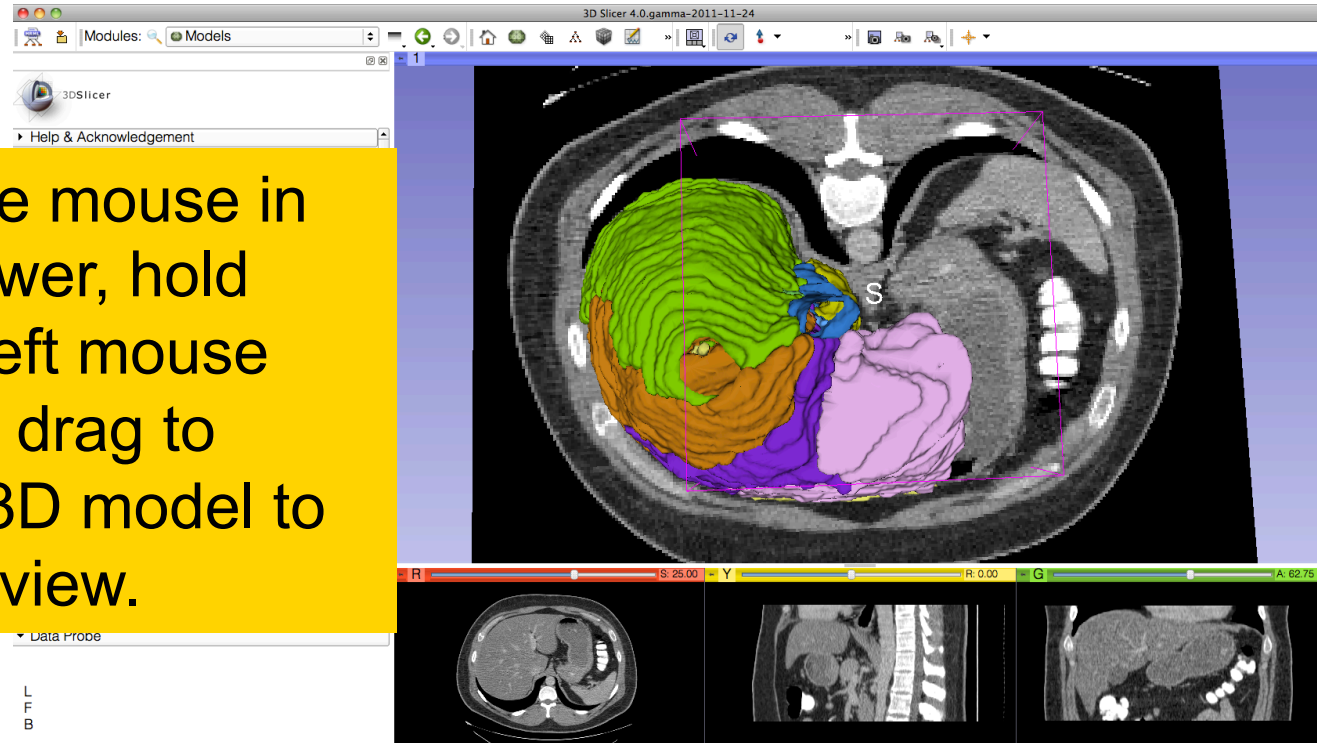


Select the model **Liver_Segment II**
Turn on/off its visibility to locate
it in the 3D viewer.



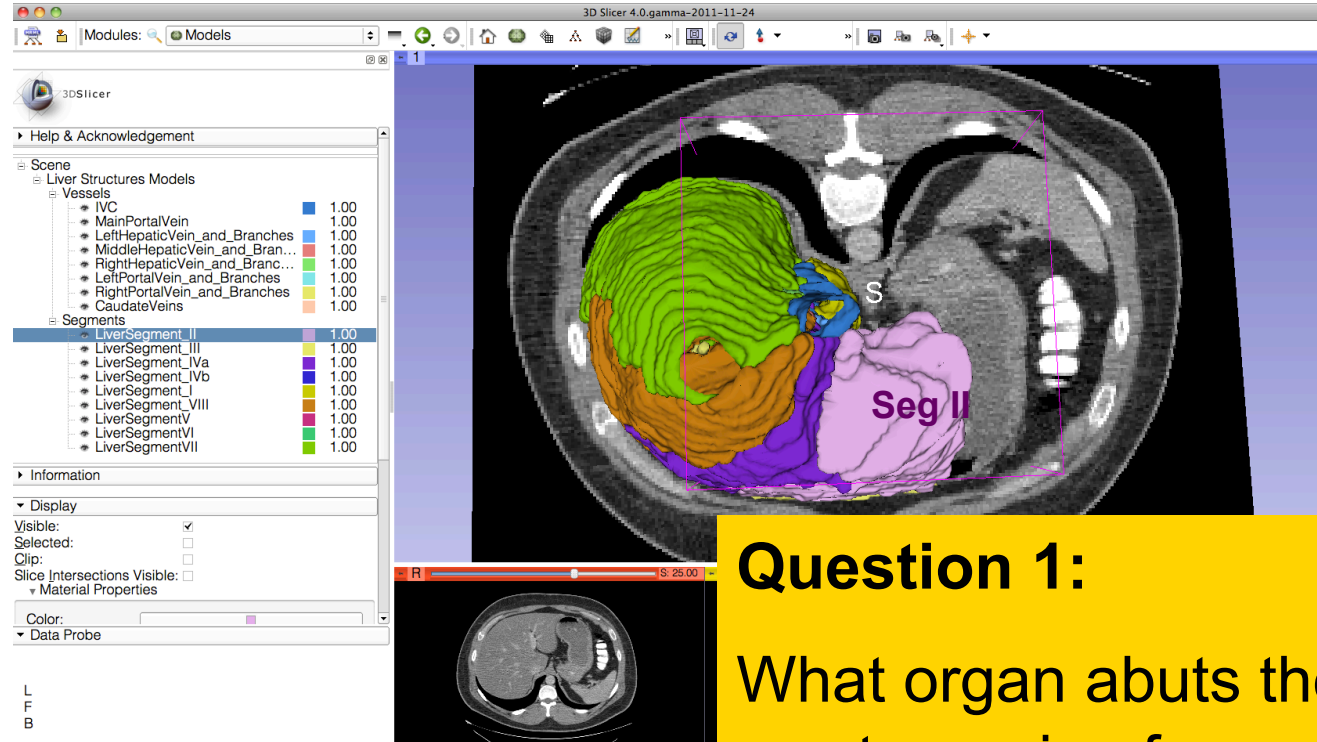
3D Exploration of Liver Segments

Position the mouse in the 3D Viewer, hold down the left mouse button and drag to orient the 3D model to a superior view.





3D Exploration of Liver Segments



Question 1:

What organ abuts the left-most margin of segment II in Patient 1?

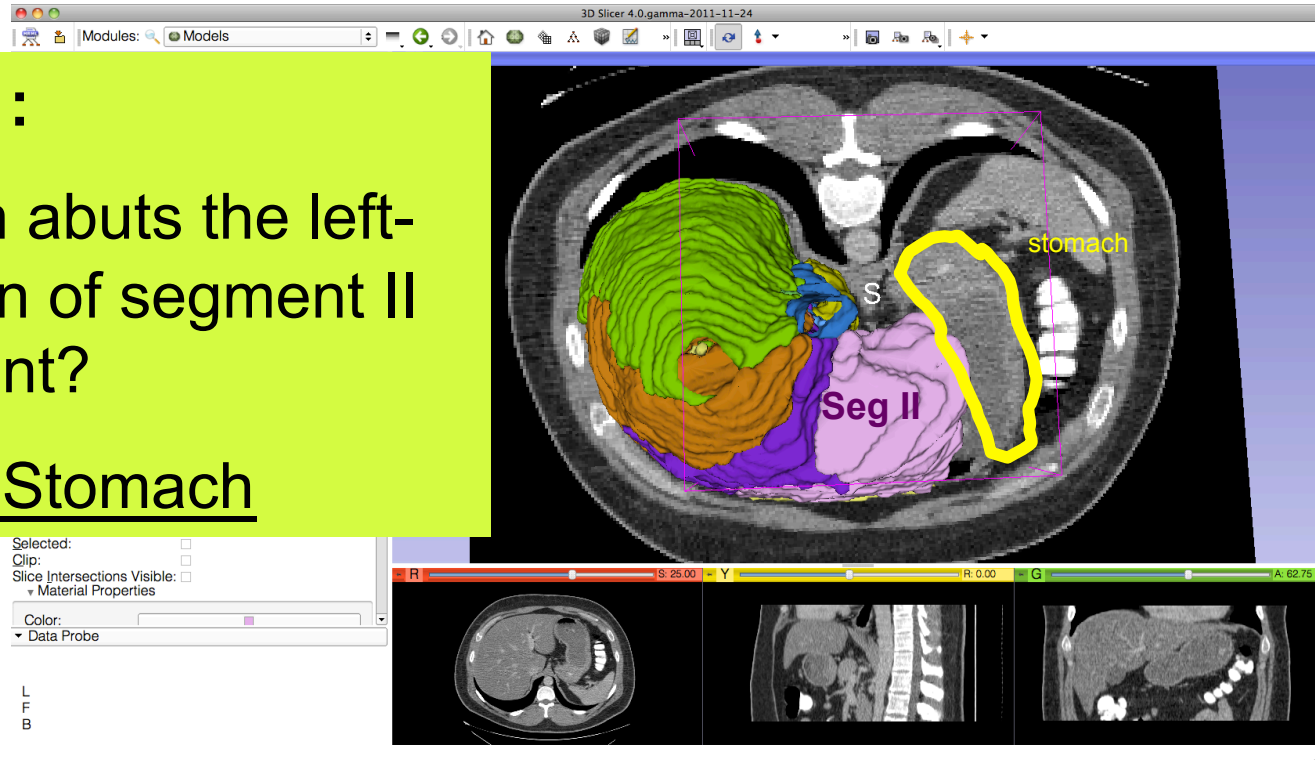


3D Exploration of Liver Segments

Question 1:

What organ abuts the left-most margin of segment II in this patient?

Answer 1: Stomach

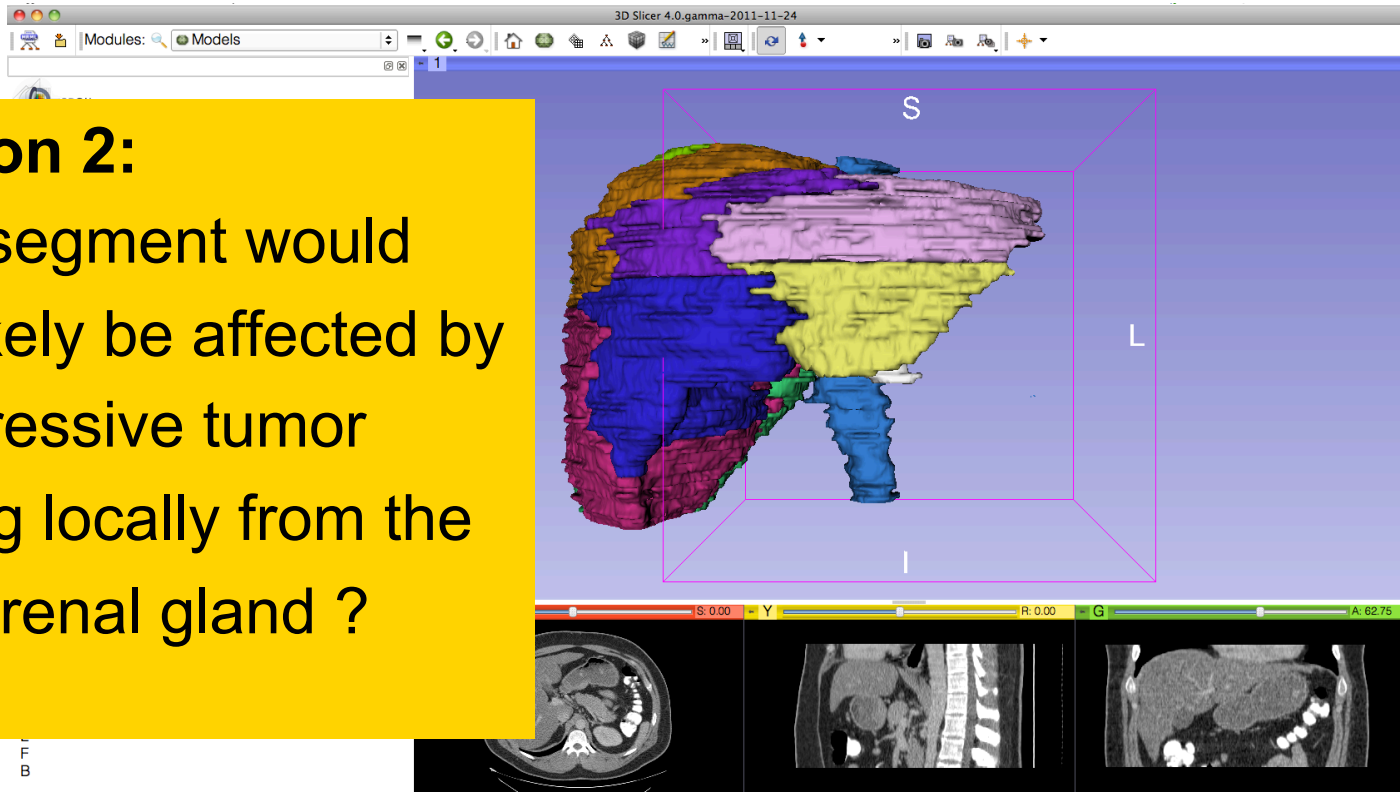




3D Exploration of Liver Segments

Question 2:

Which segment would most likely be affected by an aggressive tumor invading locally from the right adrenal gland ?



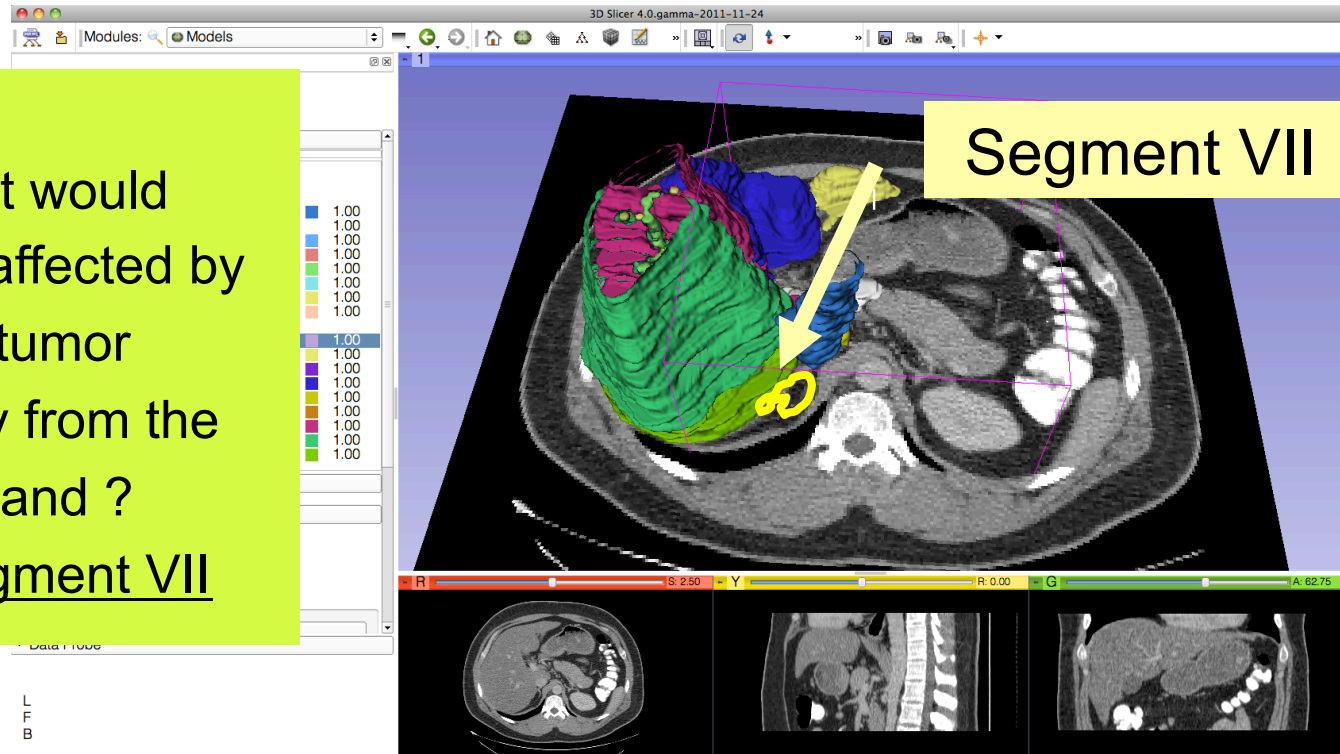

3D Exploration of Liver Segments

Question 2:

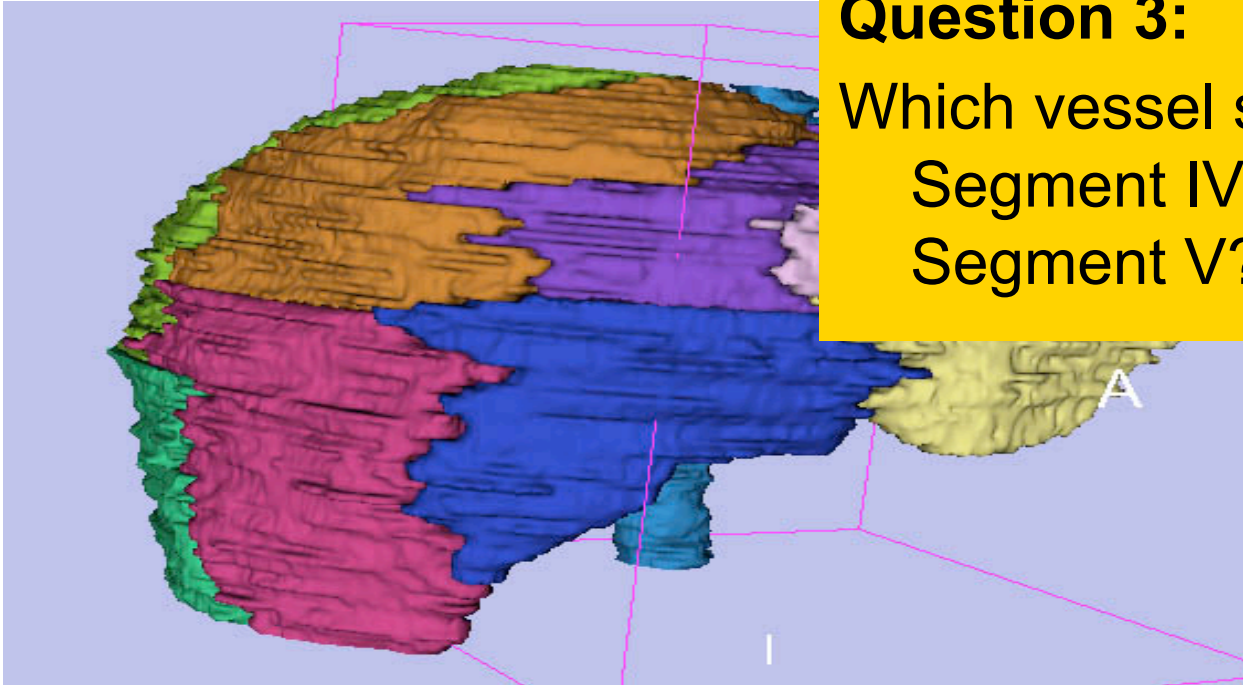Which segment would most likely be affected by an aggressive tumor invading locally from the right adrenal gland ?

Answer 2: Segment VII





3D Exploration of Liver Segments

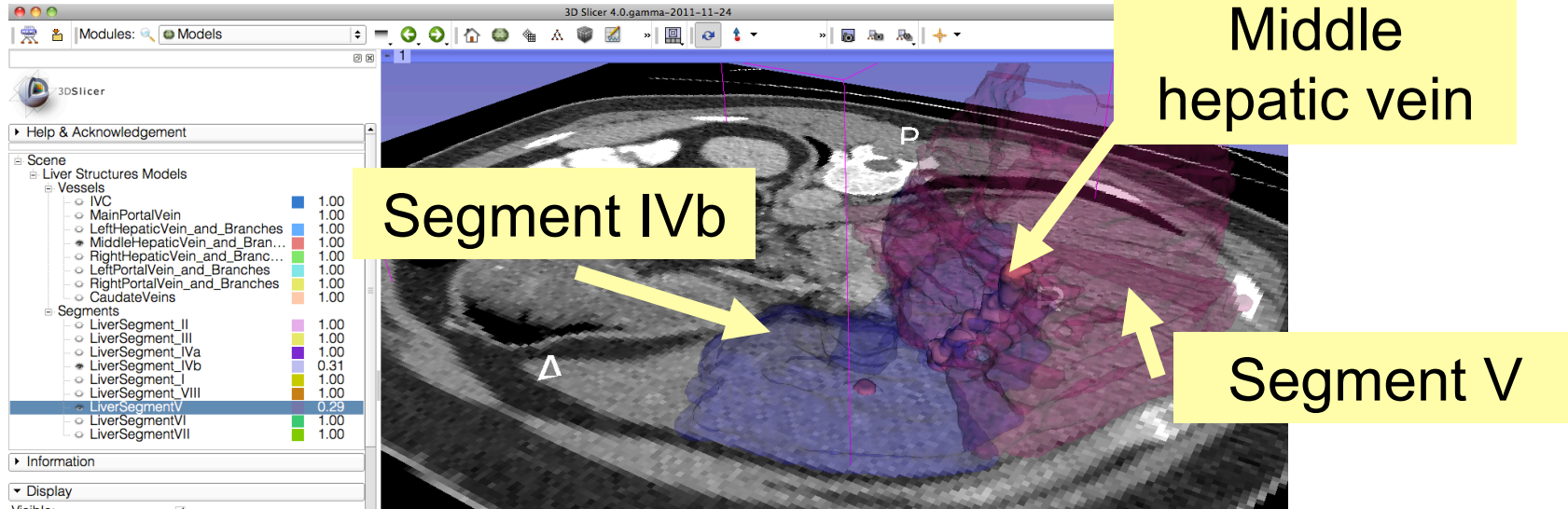


Question 3:

Which vessel separates
Segment IVb and
Segment V?



Middle Hepatic Vein



Question 3:

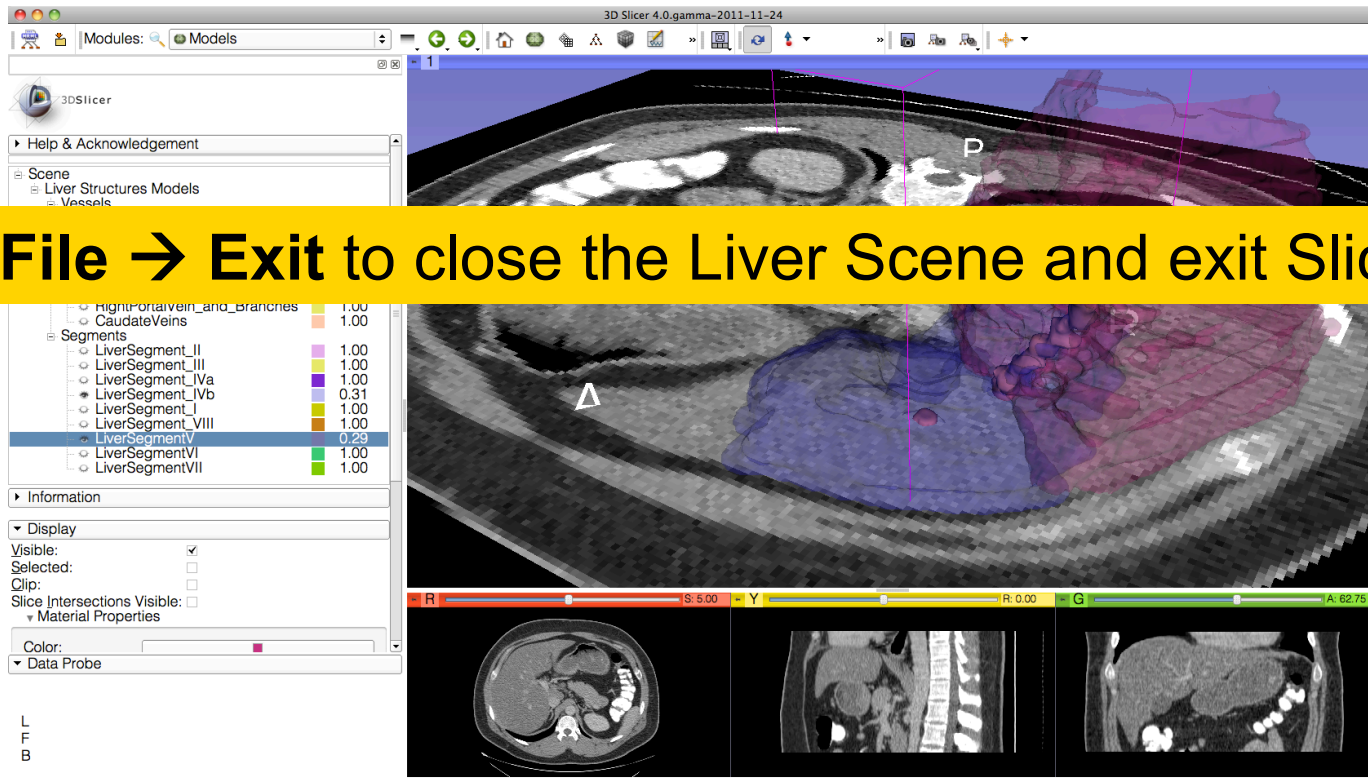Which vessel separates Segment IVb and Segment V?

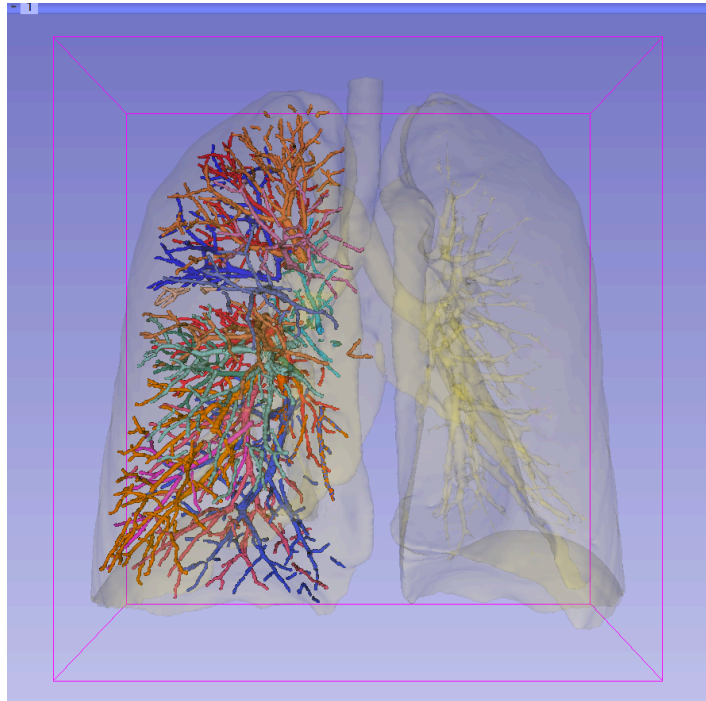
Answer 3: The middle hepatic vein



Closing the Liver Scene

Select **File** → **Exit** to close the Liver Scene and exit Slicer



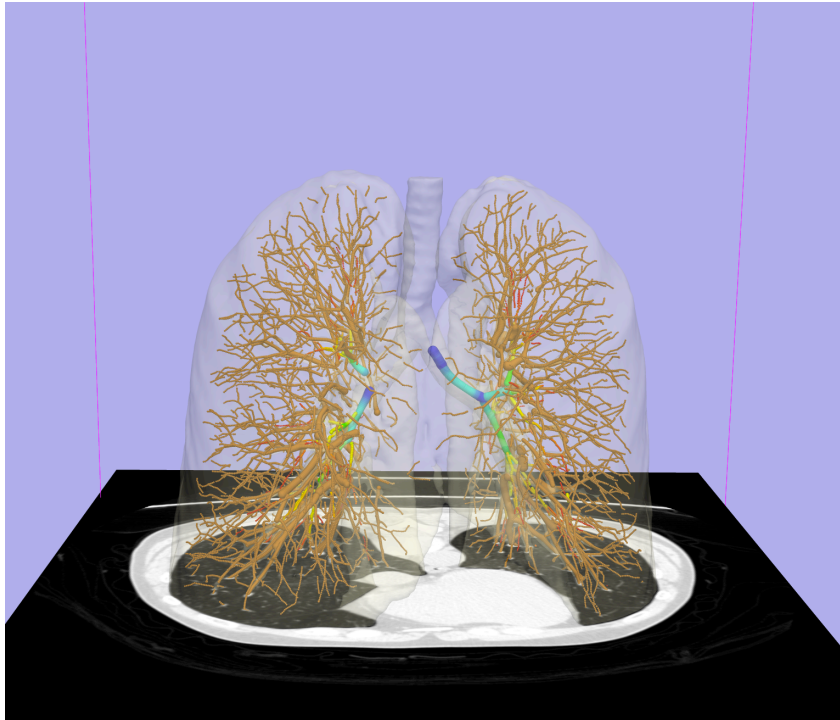


Part 4:

Interactive 3D Visualization
of the segments of the lungs



Segments of the lung



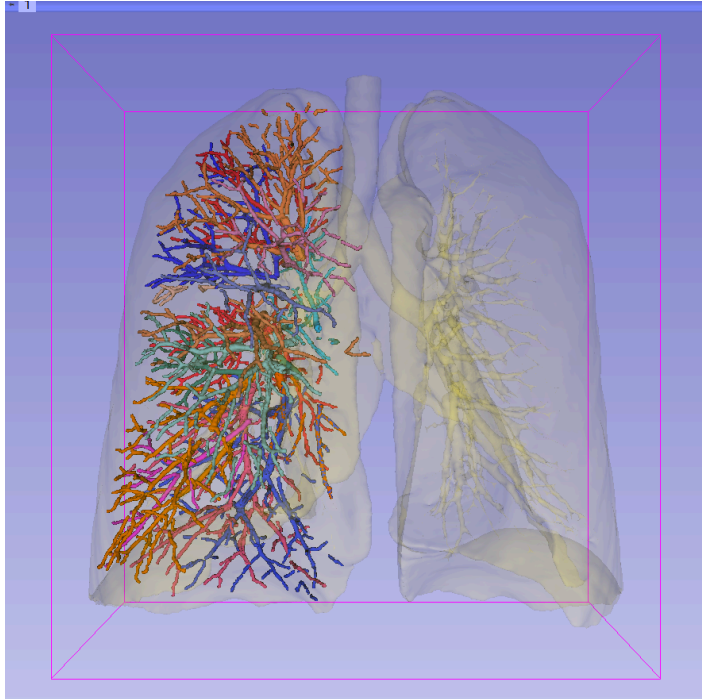
Segmentation and 3D surface reconstruction of the lung and pulmonary vessels

Acknowledgment:

Segmentation of the lung surface and vasculature:
Raul San Jose Estepar, Ph.D., George Washko, M.D., Ed Silverman, M.D. and James Ross, MSc. Brigham and Women's Hospital
(K25 HL104085) and COPDGene (01 HL089897 and U01 HL089856)



Segments of the lung

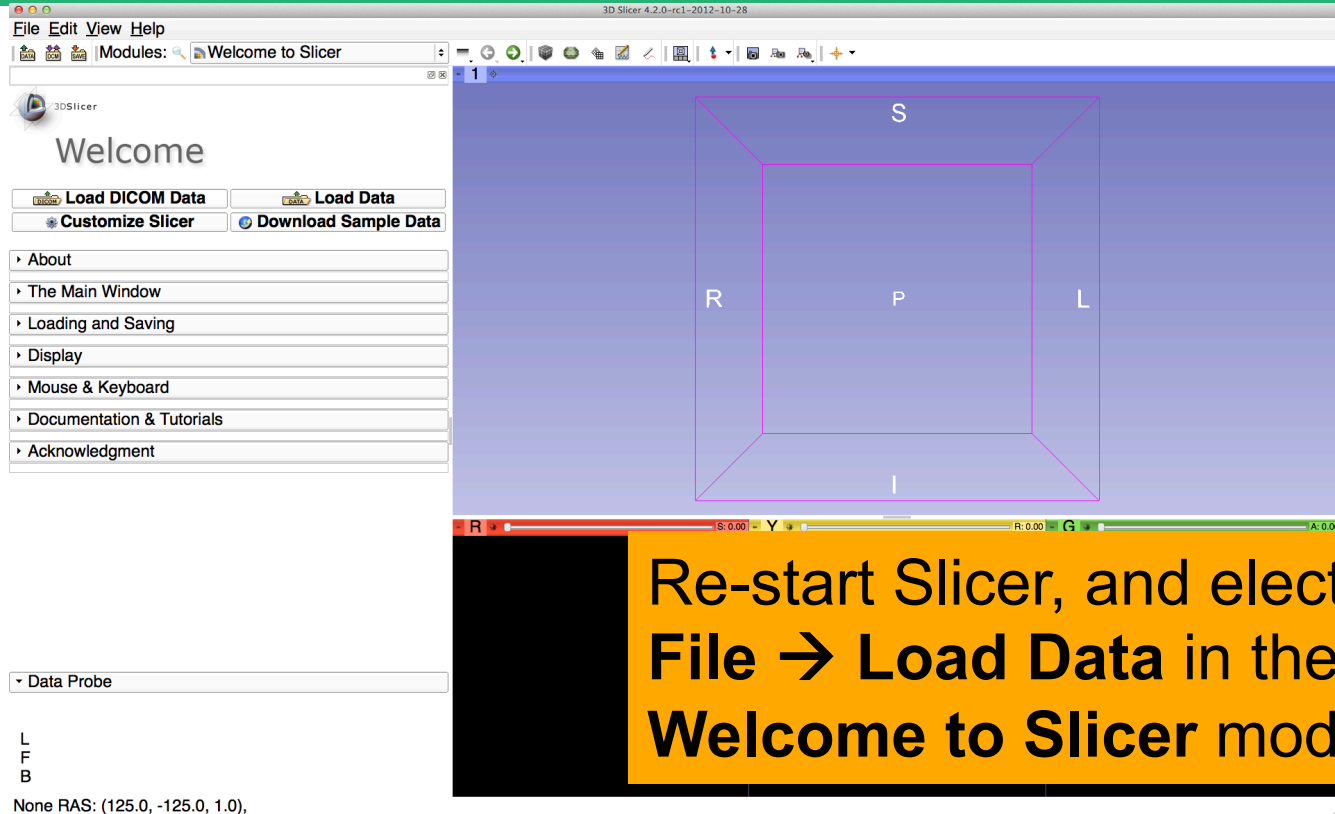


3D parcellation of arteries and veins from original model of pulmonary vessels
(Kitt Shaffer, M.D., Ph.D. - Sonia Pujol, Ph.D.)

- Right Upper Lobe (RUL)
 - RUL Pulmonary Vein
 - RUL Anterior Segment
 - RUL Apical Segment
 - RUL Posterior Segment
- Right Middle Lobe (RML)
 - RML Pulmonary Vein 1 & 2
 - RML Lateral Segment
 - RML Medial Segment
- Right Lower Lobe (RLL)
 - RLL Pulmonary Vein 1,2,3
 - RLL Anterior Basal Segment
 - RLL Medial Basal Segment
 - RLL Lateral Basal Segment
 - RLL Posterior Basal Segment



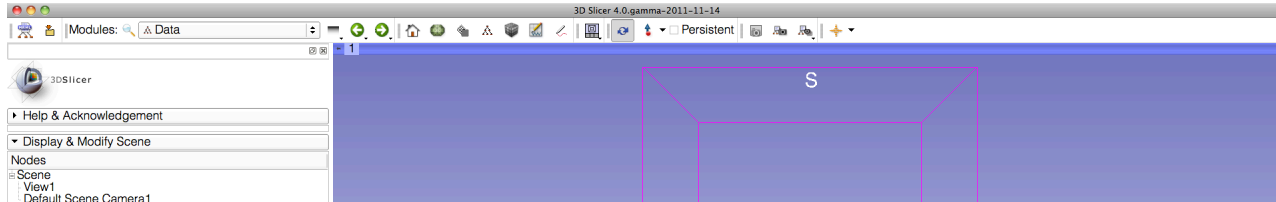
Loading the Chest Data Scene




**Re-start Slicer, and elect
File → Load Data in the
Welcome to Slicer module**



Loading the Lung Scene

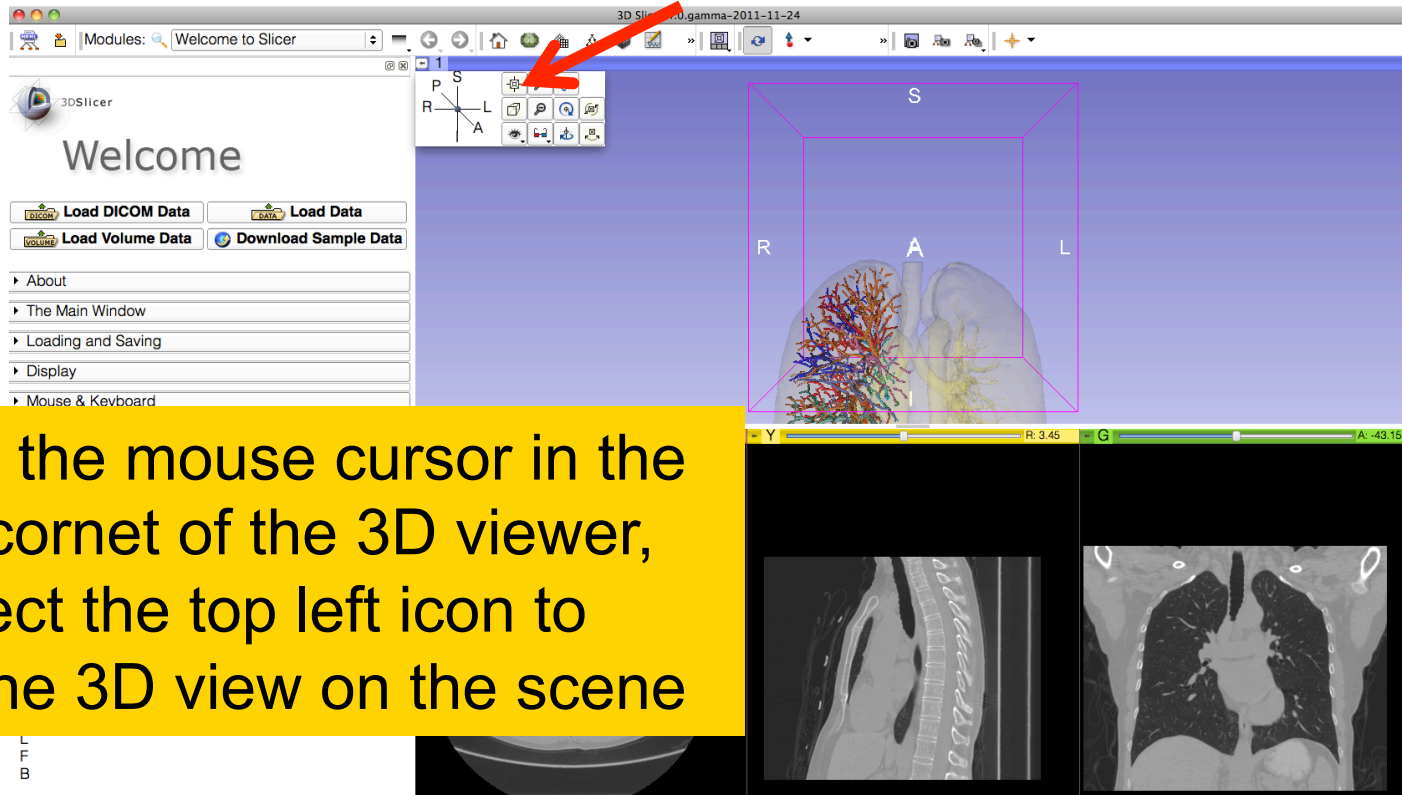


Load the file **LungSegment_Scene.mrml** located in:
**C:\Documents and Settings\Administrator\Desktop\3DSlicer
\LungData**





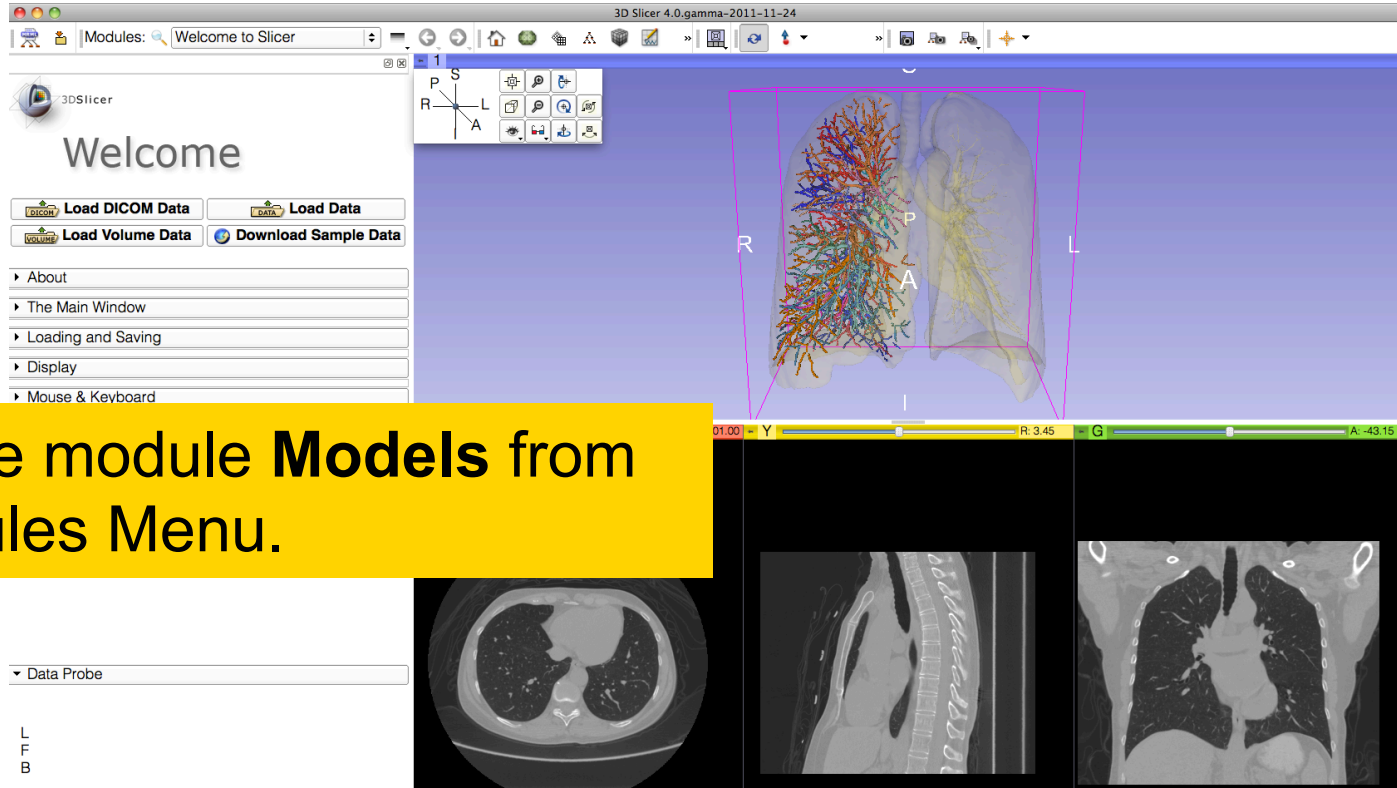
Loading the Lung Scene



Position the mouse cursor in the top left corner of the 3D viewer, and select the top left icon to center the 3D view on the scene



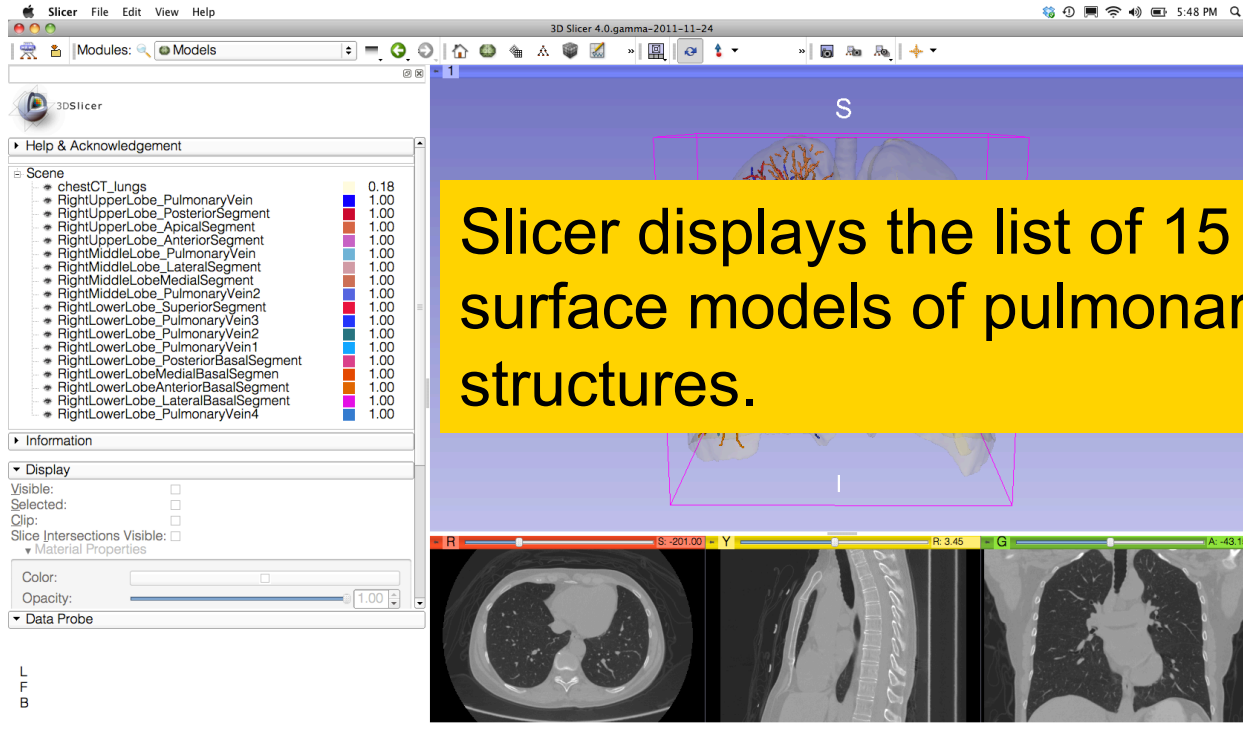
Loading the Lung Scene



Select the module **Models** from the modules Menu.

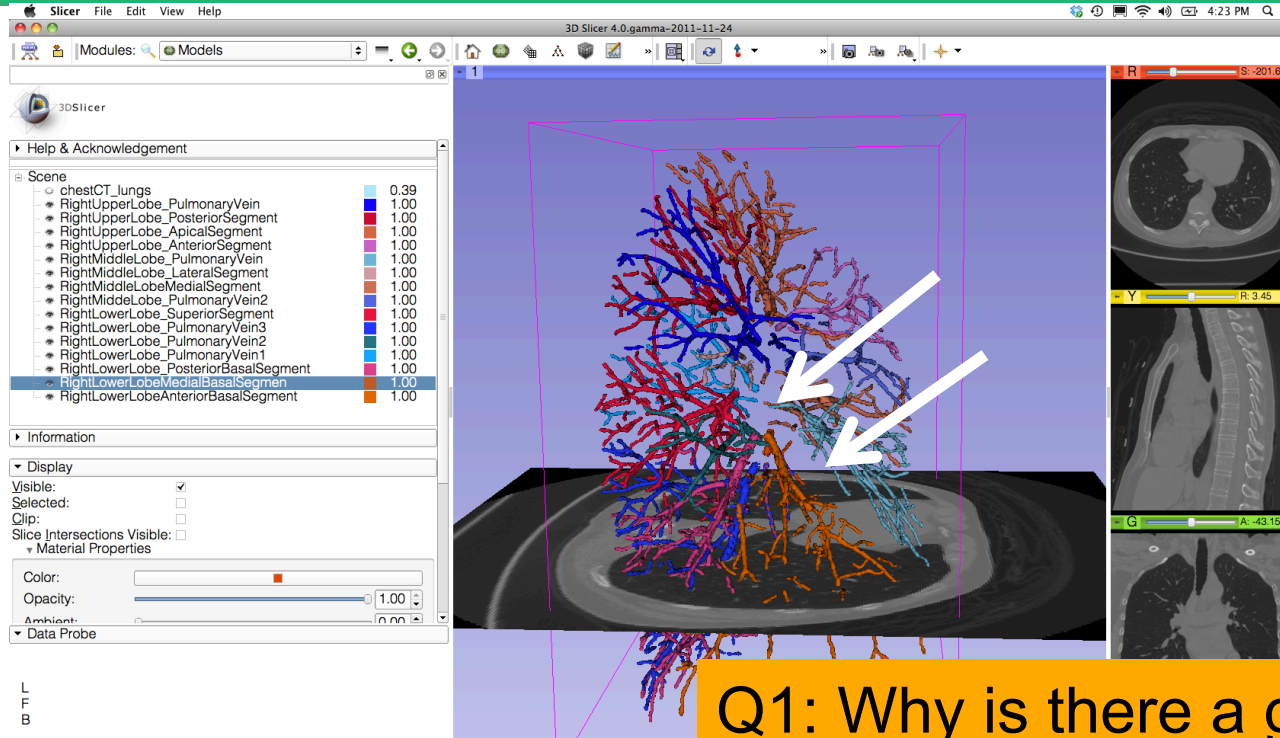


Lung Segments





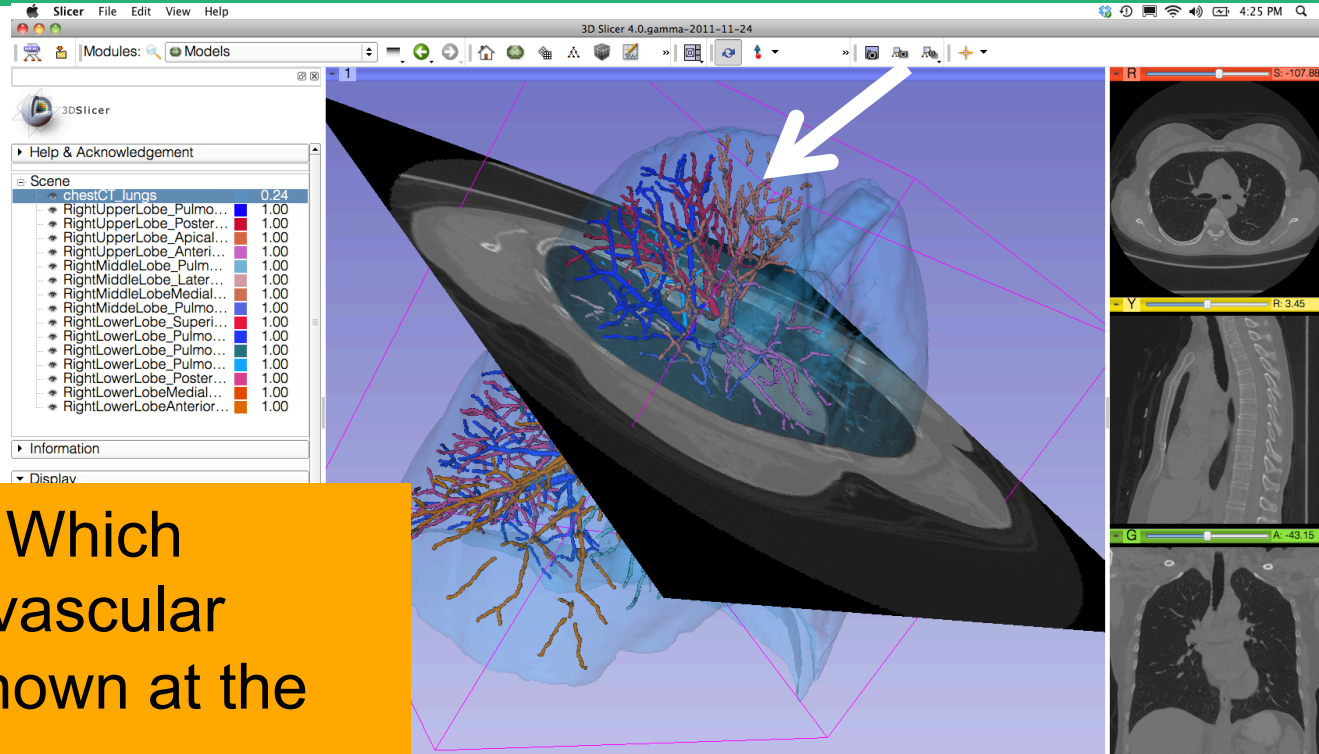
Lung Segments – Question 1



Q1: Why is there a gap in the vessels at the arrows?



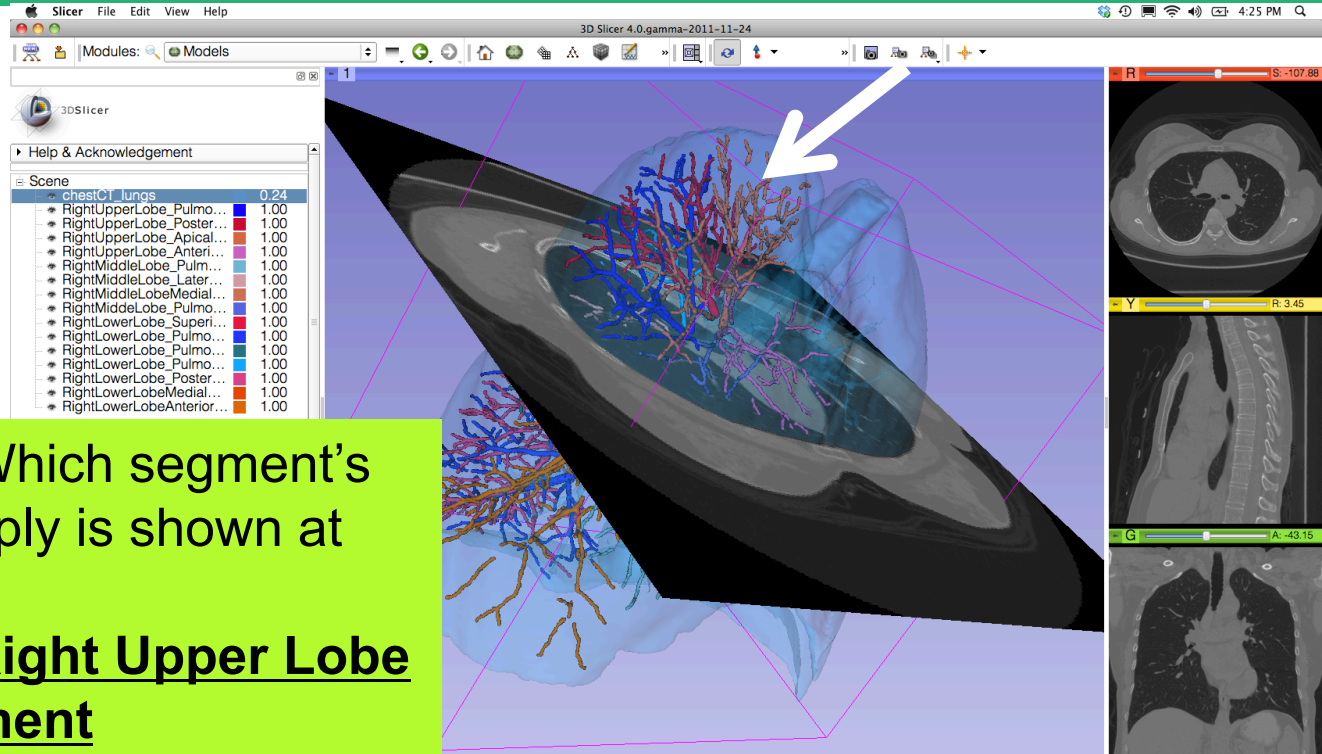
Lung Segments – Question 2



Question 2: Which segment's vascular supply is shown at the arrow?



Lung Segments – Question 2

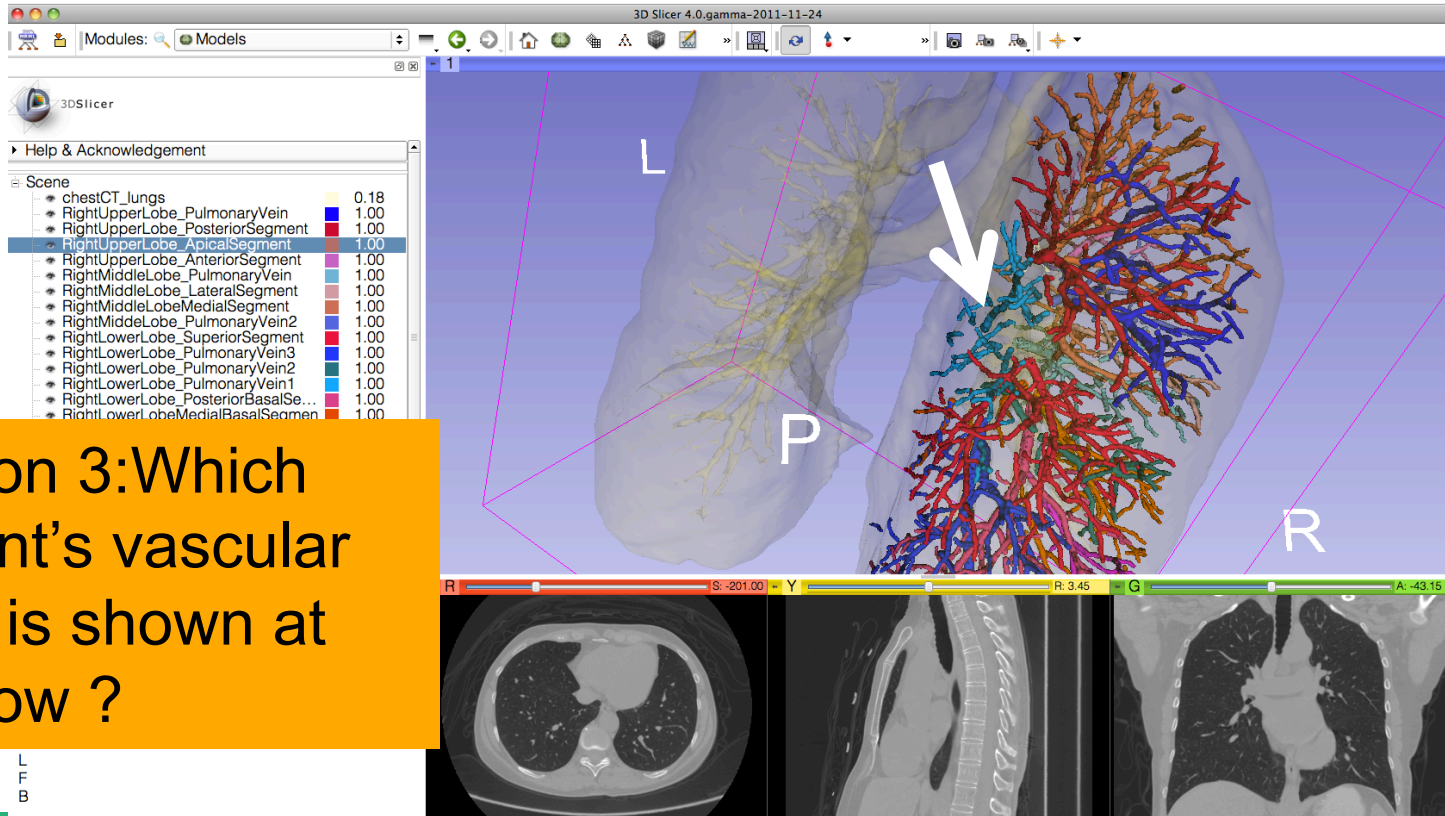


Question 2: Which segment's vascular supply is shown at the arrow?

Answer 2: Right Upper Lobe Apical Segment



Lung Segments – Question 3

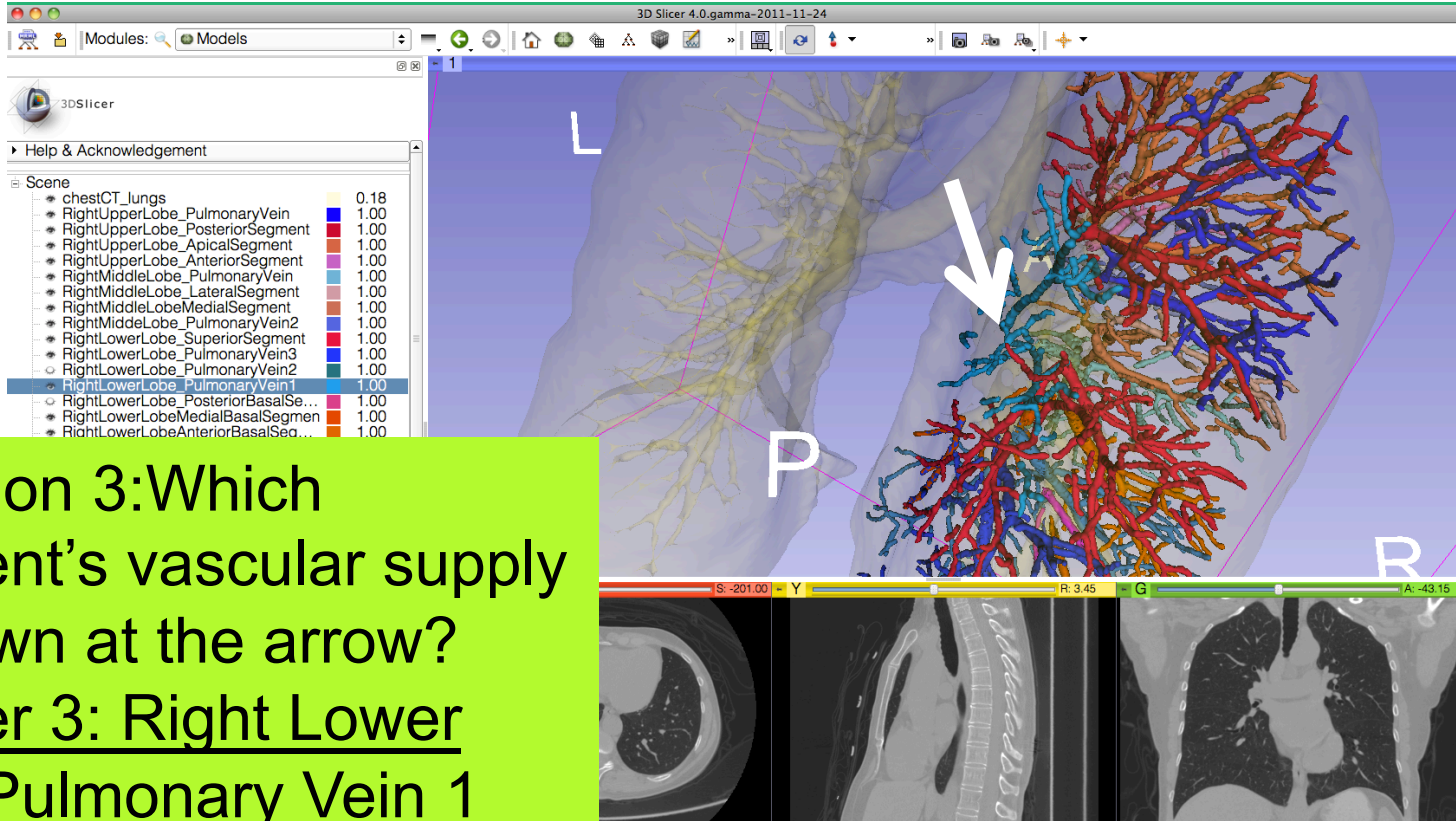


Question 3: Which segment's vascular supply is shown at the arrow?

L
F
B



Lung Segments – Question 3



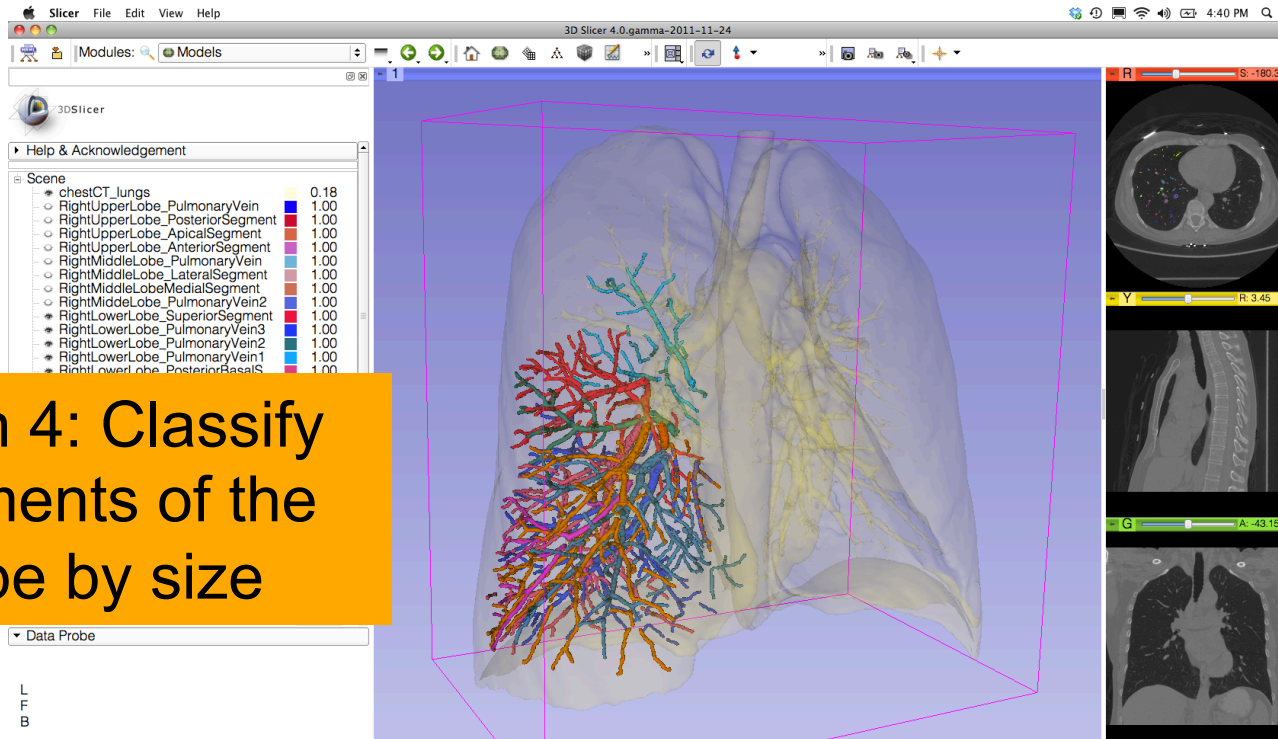
Question 3: Which segment's vascular supply is shown at the arrow?

Answer 3: Right Lower Lobe Pulmonary Vein 1



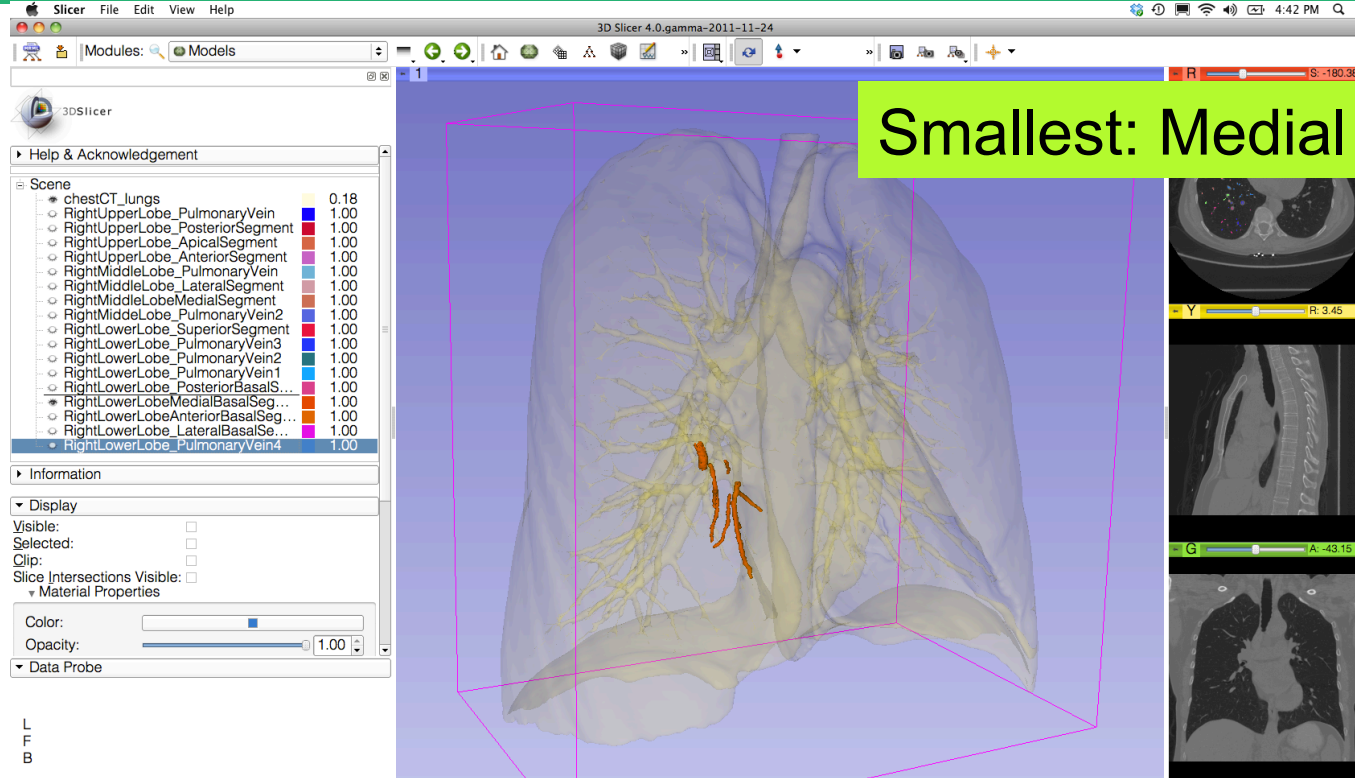
Lung Segments – Question 4

Question 4: Classify the segments of the lower lobe by size



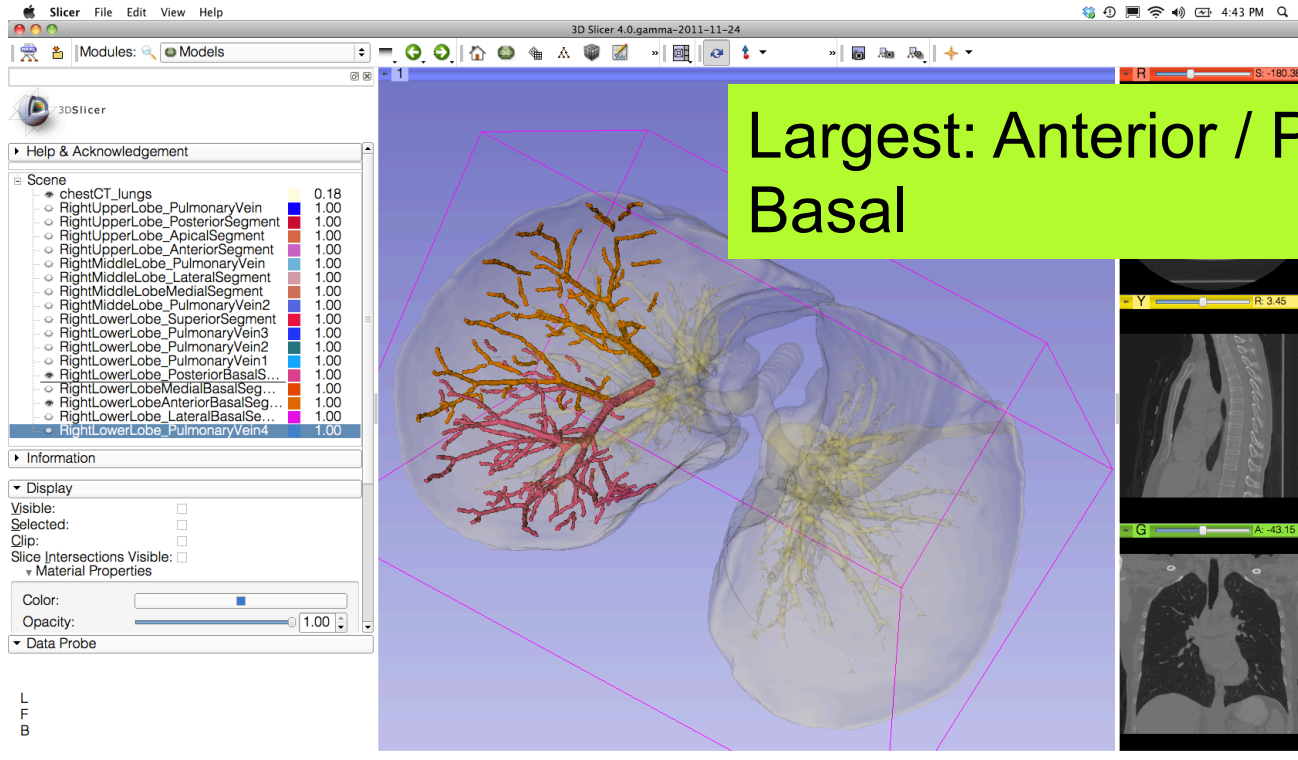


Lung Segments – Question 4



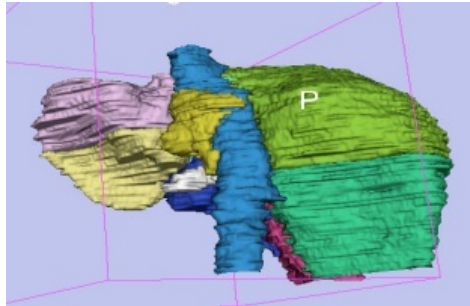
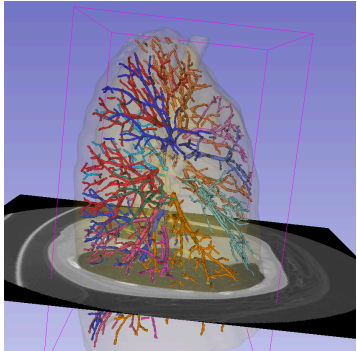
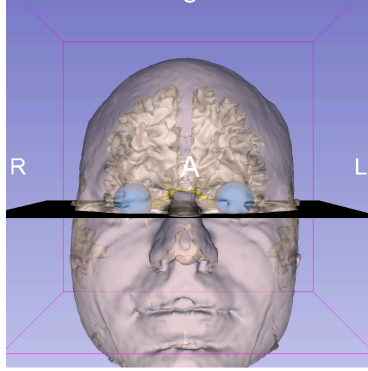
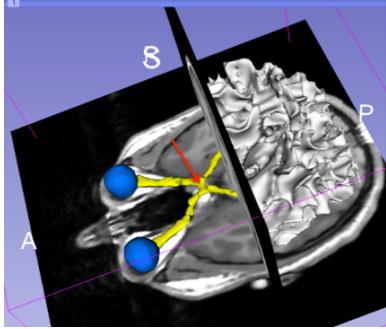


Lung Segments – Question 4





3D Visualization of DICOM images



- Interactive user-interface to load and manipulate greyscale volumes, labelmaps and 3D models.
- User-defined 3D view of the anatomy
- 3D Open-source platform for Linux, Mac and Windows



Acknowledgments

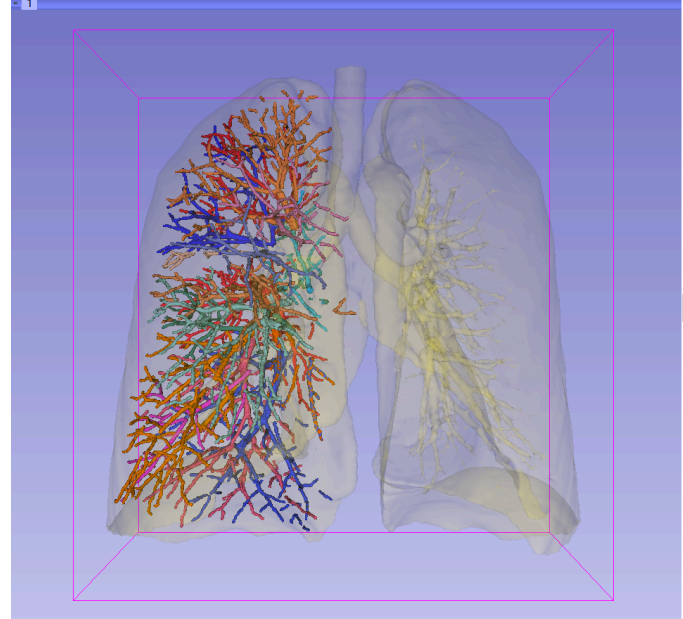


National Alliance for Medical Image Computing (NA-MIC)
(NIH Grant U54EB005149)



Neuroimage Analysis Center (NAC)
(NIH Grant P41 RR013218)

www.slicer.org
www.na-mic.org



Questions and comments: spujol@bwh.harvard.edu